

Indian Journal of Anatomy

Editor-in-Chief

Col (Dr) Sushil Kumar

Professor & Head, Dept. of Anatomy,
Armed Forces Medical College,
Pune, Maharashtra 411040, India.

Former Editor-in-Chief

Dope Santoshkumar Ankushrao

Govt. Medical College, Latur

International Editorial Board Members

Nitin Vishwakarma, Oman

Anand L Kulkarni, USA

Eduardo Rocha, Portugal

J. Ramon Merida Velasco, Spain

Luis-Alfonso Arráez-Aybar, Spain

National Editorial Board Members

B Senthil Kumar, Salem, Tamilnadu

Najma Mobin, Mysore

Sukre Shivaji Balabhau, Aurangabad

Sayee Rajangam, Bangalore

Manisha B. Sinha, Raipur

Harish A. Wankhede, Miraj

Dipti A. Nimje, Dhule

Surajit Ghatak, Jodhpur

Pradeep Bokariya, Wardha

S. P. Sawant, Mumbai

Sarah Ralte, Shillong

Rosemol Xaviour, Thrissur

Daksha Dixit P, Karnataka

Managing Editor

A. Lal

Publication Editor

Manoj Kumar Singh

Indexing Information: Index Copernicus, Poland; Google Scholar; Pro Quest, USA; Genamics Journal Seek.

All rights reserved. The views and opinions expressed are of the authors and not of the **Indian Journal of Anatomy**. IJA does not guarantee directly or indirectly the quality or efficacy of any product or service featured in the advertisement in the journal which are purely commercial.

Printed at Saujanya Printing Press, B-303, Okhla Industrial Area Phase-1, New Delhi - 20

Red Flower Publication Pvt. Ltd.

48/41-42 DSIDC, Pocket-II, Mayur Vihar Phase-I
Delhi - 110 091(India)

Phone: 91-11-22756995, 22754205, 45796900

E-mail: info@rfppl.co.in

Website: www.rfppl.co.in

The Indian Journal of Anatomy (pISSN: 2320-0022, eISSN: 2455-622X) is a print and online journal of the **Red Flower Publication Pvt. Ltd.** publishes original and peer-reviewed articles, for the dissemination of anatomical knowledge with clinical, surgical and imaging guidance. Includes articles of history, reviews and biographies, locomotors, splachnology, neuroanatomy, imaging anatomy, anatomical variations, anatomical techniques, education and pedagogy in anatomy, Human Anatomy, Veterinary Anatomy, Embryology, Gross Anatomy (Macroscopic), Microscopic Anatomy (Histology, Cytology), Plant Anatomy (Phytotomy), Comparative Anatomy, editorials, letters to the editor, and case reports. Articles of veterinary anatomy, comparative and other morphological sciences are accepted. Indian Journal of Diabetes and Endocrinology

Subscription Information

Institutional (1 year) INR8500/USD664

Payment Methods:

Bank draft / cashier's order / cheque / demand draft / money order should be in the name of **Red Flower Publication Pvt. Ltd.** payable at **Delhi**.

International Bank transfer / bank wire / electronic funds transfer / money remittance / money wire / telegraphic transfer / telex

1. **Complete Bank Account No.** 604320110000467
2. **Beneficiary Name (As per Bank Pass Book):** Red Flower Publication Pvt. Ltd.
3. **Beneficiary Address:** 48/41-42, DSIDC, Pocket-II, Mayur Vihar Phase-I, Delhi - 110 091(India)
4. **Bank & Branch Name:** Bank of India; Mayur Vihar
5. **Bank Address & Phone Number:** 13/14, Sri Balaji Shop, Pocket II, Mayur Vihar Phase- I, New Delhi - 110091 (India); Tel: 22750372, 22753401. **Email:** mayurvihar.newdelhi@bankofindia.co.in
6. **MICR Code:** 110013045
7. **Branch Code:** 6043
8. **IFSC Code:** BKID0006043 (used for RTGS and NEFT transactions)
9. **Swift Code:** BKIDINBBDOS
10. **Beneficiary Contact No. & E-mail ID:** 91-11-22754205, E-mail: sales@rfppl.co.in
11. **PAN No.**AAECR7434A

Send all orders to: **Red Flower Publication Pvt. Ltd.**, 48/41-42, DSIDC, Pocket-II, Mayur Vihar Phase-I, Delhi - 110 091, India, Mobile: 8130750089, Phone: 91-11-45796900, 22754205, 22756995, E-mail: sales@rfppl.co.in, Website: www.rfppl.co.in

Contents

Original Articles

- A Morphological Study on Cervical Vertebrae and It's Clinical Relevance** 85
Padmalatha K, Kalpana S Udupa, Bindusar G Hosmani
- Estimation of Stature from Cephalo-Facial Dimensions:
A Cross Sectional Study in Central India** 91
Monali Hiwarkar, Anjali Prasad, Onjal Taywade
- Correlation of Human Height with Foot Dimensions:
A Study in Young Population of Central India** 95
Sundip Charmode Hemant, Pujari Dinanath Keshavbhat,
Kadlimatti Huchchesha shivappa
- Morphological and Morphometric Study of Scaphoid
Bone in South Coastal Population** 101
Madala Venkateswara Rao, Lattupalli Hema
- Study of Variation in the Position of Greater Palatine
Foramen in North Karnataka Population** 107
Ratna Prabha J, Uday Kumar
- A Study on Foramen Magnum Morphometry in 3-Dimensional CT Scans and
Dry Skulls and its Neurosurgical and Forensic Implications** 111
Venkatesh G Kamath, Md Tabrej Alam
- Correlative Study of Length and Breadth of Mastoid Process with
Cranial Index in North Karnataka Crania** 117
Ratna Prabha J, Uday Kumar

Case Report

- Abnormal Origin of the Right Coronary Artery:
A Case Report with Literature Review** 123
Dhanesh Kumar Sharma, Meryl Rachel John, Nikita Chaudhary
- Guidelines for Authors** 128

Revised Rates for 2019 (Institutional)

Title of the Journal	Frequency	India(INR)	India(INR)	Outside	Outside
		Print Only	Online Only	India(USD) Print Only	India(USD) Online Only
Dermatology International	Semiannual	5500	5000	430	391
Gastroenterology International	Semiannual	6000	5500	469	430
Indian Journal of Anatomy	Quarterly	8500	8000	664	625
Indian Journal of Anesthesia and Analgesia	Bi-monthly	7500	7000	586	547
Indian Journal of Cancer Education and Research	Semiannual	9000	8500	703	664
Indian Journal of Communicable Diseases	Semiannual	8500	8000	664	625
Indian Journal of Dental Education	Quarterly	5500	5000	430	391
Indian Journal of Diabetes and Endocrinology	Semiannual	8000	7500	597	560
Indian Journal of Genetics and Molecular Research	Semiannual	7000	6500	547	508
Indian Journal of Hospital Administration	Semiannual	7000	6500	547	508
Indian Journal of Hospital Infection	Semiannual	12500	12000	938	901
Indian Journal of Medical & Health Sciences	Semiannual	7000	6500	547	508
Indian Journal of Pathology: Research and Practice	Bi-monthly	12000	11500	938	898
Indian Journal of Preventive Medicine	Semiannual	7000	6500	547	508
International Journal of Neurology and Neurosurgery	Quarterly	10500	10000	820	781
International Physiology	Triannual	7500	7000	586	547
Journal of Cardiovascular Medicine and Surgery	Quarterly	10000	9500	781	742
Journal of Global Medical Education and Research	Semiannual	5900	5500	440	410
Journal of Global Public Health	Semiannual	12000	11500	896	858
Journal of Microbiology and Related Research	Semiannual	8500	8000	664	625
Journal of Organ Transplantation	Semiannual	26400	25900	2063	2023
Journal of Orthopedic Education	Triannual	5500	5000	430	391
Journal of Pharmaceutical and Medicinal Chemistry	Semiannual	16500	16000	1289	1250
Journal of Practical Biochemistry and Biophysics	Semiannual	7000	6500	547	508
Journal of Radiology	Semiannual	8000	7500	625	586
New Indian Journal of Surgery	Bi-monthly	8000	7500	625	586
Ophthalmology and Allied Sciences	Triannual	6000	5500	469	430
Otolaryngology International	Semiannual	5500	5000	430	391
Pediatric Education and Research	Quarterly	7500	7000	586	547
Physiotherapy and Occupational Therapy Journal	Quarterly	9000	8500	703	664
Urology, Nephrology and Andrology International	Semiannual	7500	7000	586	547
Indian Journal of Maternal-Fetal & Neonatal Medicine	Semiannual	9500	9000	742	703
Indian Journal of Obstetrics and Gynecology	Quarterly	9500	9000	742	703
Indian Journal of Emergency Medicine	Quarterly	12500	12000	977	938
Indian Journal of Trauma and Emergency Pediatrics	Quarterly	9500	9000	742	703
Journal of Emergency and Trauma Nursing	Semiannual	5500	5000	430	391
Indian Journal of Forensic Medicine and Pathology	Quarterly	16000	15500	1250	1211
Indian Journal of Forensic Odontology	Semiannual	5500	5000	430	391
Indian Journal of Legal Medicine	Semiannual	8500	8000	664	625
International Journal of Forensic Sciences	Semiannual	10000	9500	781	742
Journal of Forensic Chemistry and Toxicology	Semiannual	9500	9000	742	703
Community and Public Health Nursing	Triannual	5500	5000	430	391
Indian Journal of Surgical Nursing	Triannual	5500	5000	430	391
International Journal of Pediatric Nursing	Triannual	5500	5000	430	391
International Journal of Practical Nursing	Triannual	5500	5000	430	391
Journal of Gerontology and Geriatric Nursing	Semiannual	5500	5000	430	391
Journal of Nurse Midwifery and Maternal Health	Triannual	5500	5000	430	391
Journal of Psychiatric Nursing	Triannual	5500	5000	430	391
Indian Journal of Ancient Medicine and Yoga	Quarterly	8000	7500	625	586
Indian Journal of Law and Human Behavior	Semiannual	6000	5500	469	430
Indian Journal of Medical Psychiatry	Semiannual	8000	7500	625	586
Indian Journal of Biology	Semiannual	5500	5000	430	391
Indian Journal of Library and Information Science	Triannual	9500	9000	742	703
Indian Journal of Research in Anthropology	Semiannual	12500	12000	977	938
Indian Journal of Waste Management	Semiannual	9500	8500	742	664
International Journal of Political Science	Semiannual	6000	5500	450	413
Journal of Social Welfare and Management	Triannual	7500	7000	586	547
International Journal of Food, Nutrition & Dietetics	Triannual	5500	5000	430	391
Journal of Animal Feed Science and Technology	Semiannual	7800	7300	609	570
Journal of Food Additives and Contaminants	Semiannual	5000	4500	391	352
Journal of Food Technology and Engineering	Semiannual	5000	4500	391	352
Indian Journal of Agriculture Business	Semiannual	5500	5000	413	375
Indian Journal of Plant and Soil	Semiannual	6500	6000	508	469

Terms of Supply:

1. Agency discount 12.5%. Issues will be sent directly to the end user, otherwise foreign rates will be charged.
2. All back volumes of all journals are available at current rates.
3. All Journals are available free online with print order within the subscription period.
4. All legal disputes subject to Delhi jurisdiction.
5. Cancellations are not accepted orders once processed.
6. Demand draft / cheque should be issued in favour of "Red Flower Publication Pvt. Ltd." payable at Delhi
7. Full pre-payment is required. It can be done through online (<http://rfppl.co.in/subscribe.php?mid=7>).
8. No claims will be entertained if not reported within 6 months of the publishing date.
9. Orders and payments are to be sent to our office address as given above.
10. Postage & Handling is included in the subscription rates.
11. Subscription period is accepted on calendar year basis (i.e. Jan to Dec). However orders may be placed any time throughout the year.

Order from

Red Flower Publication Pvt. Ltd., 48/41-42, DSIDC, Pocket-II, Mayur Vihar Phase-I, Delhi - 110 091 (India),

Mobile: 8130750089, Phone: 91-11-45796900, 22754205, 22756995 E-mail: sales@rfppl.co.in, Website: www.rfppl.co.in

A Morphological Study on Cervical Vertebrae and It's Clinical Relevance

Padmalatha K¹, Kalpana S Udupa², Bindusar G Hosmani³

Abstract

Background: Cervical vertebrae are seven in number. C3-6 are typical whereas C1 (Atlas), C2 (Axis) and C7 (Vertebrae prominens) are atypical. The cervical vertebrae are identified by the presence of foramen transversarium in the transverse process. Skeletal abnormalities of cervical region or in craniocervical region are of interest to anatomists, orthopaedicians, neurologists, neurosurgeons and even orthodontists. These abnormalities may result in severe neck pain, decreased neck mobility, muscular weakness and sensory deficits of both upper limbs and sudden unexpected deaths. **Aims and Objectives:** The present study is carried out to know the incidence of variations with respect to it's morphology seen in both typical and atypical cervical vertebrae. **Materials and Methods:** The study is conducted on a total of 210 dry human adult cervical vertebrae of both sexes obtained from Department of Anatomy, ESIC Medical College & PGIMS, Rajajinagar, Bengaluru. The cervical vertebrae showing variations with respect to it's morphology were identified and the photographs were taken. **Results:** We came across the presence of fused cervical vertebrae (C2, 3 & 4) and (C6 & 7), arcuate foramen, elongated odontoid process, assymetrical foramen transversarium and double foramen transversarium. **Conclusion:** A thorough knowledge of these variations will be helpful for neurosurgeons, radiologists, head & neck and vascular surgeons.

Keywords: Cervical Vertebrae; Foramen Transversarium; Arcuate Foramen; Odontoid Process; Fused Vertebrae.

How to cite this article:

Padmalatha K, Kalpana S Udupa, Bindusar G Hosmani. A Morphological Study on Cervical Vertebrae and It's Clinical Relevance. Indian J Anat. 2019;8(2):85-89.

Introduction

Cervical vertebrae are the smallest of the moveable vertebrae and are characterized by a foramen in each transverse process. They are classified as atypical or peculiar cervical vertebrae which includes first, second and seventh vertebrae, and typical cervical vertebrae which includes third, fourth, fifth and sixth vertebrae [1].

Foramen transversarium which is the

characteristic feature of cervical vertebrae is formed by the vestigial costal element fused to the body and the true transverse process of vertebra. The vertebral vessels and nervous plexus are caught between these two bony parts and closed laterally by costotransverse bar which is a thin plate of bone that connects the rib element to the original transverse process [2].

Materials and Methods

Two hundred and ten dried human cervical vertebrae were obtained from Department of Anatomy at ESIC Medical College & PGIMS, Rajajinagar Bengaluru to study the variations with respect to morphology of cervical vertebrae, it's incidence and clinical relevance. All the cervical vertebrae were examined, defective bones were excluded from the study. Cervical vertebrae showing variations with respect to morphology were compiled and photographed.

Author's Affiliation: ¹Associate Professor ^{2,3}Intern, Department of Anatomy, ESIC Medical College & Post Graduate Institute of Medical Science and Research, Bengaluru, Karnataka 560010, India.

Corresponding Author: Padmalatha K, Associate Professor, Department of Anatomy, ESIC Medical College & Post Graduate Institute of Medical Science and Research, Bengaluru, Karnataka 560010, India.

E-mail: padduanat@gmail.com

Received 15.03.2019 | Accepted 16.04.2019

Results

We came across the presence of fused cervical vertebrae in two, firstly where second, third and fourth vertebrae were fused and in second bone where sixth and seventh cervical vertebrae were fused [Figs. 1a,1b,2a,2b,3a &3b] & [Table 1].

Fused Cervical Vertebrae [2,3,4]

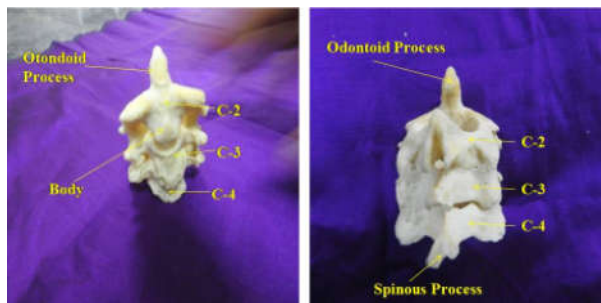


Fig. 1a: Anterior View **Fig. 1b:** Posterior View

Fused Cervical vertebrae [6 & 7]

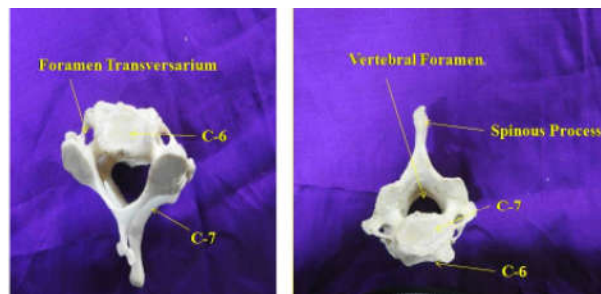


Fig. 2a: Superior View **Fig. 2b:** Inferior view

Fused Cervical Vertebrae [6 & 7]

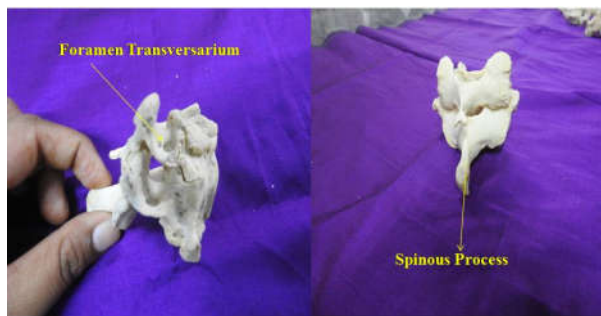

Fig. 3a: Lateral View **Fig. 3b:** Posterior View

Table 1: Incidence of Fused Cervical Vertebrae

Type of Variation	No of cases	Incidence%
Fused Cervical Vertebrae (2,3 & 4) & (6 & 7)	02	0.95

Two bones showing the presence of arcuate foramen, both the bones showing presence of

arcuate foramen unilaterally on the left side. [Figure 4 & 5] & [Table 2].

Arcuate Foramen

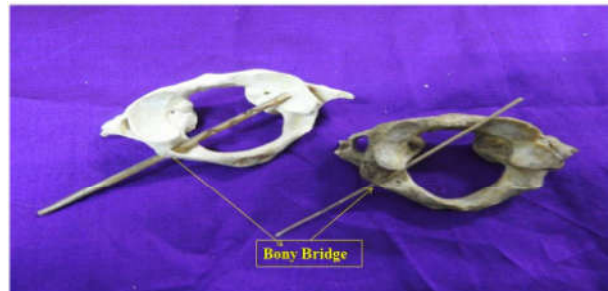

Fig. 4: Superior View

Arcuate Foramen

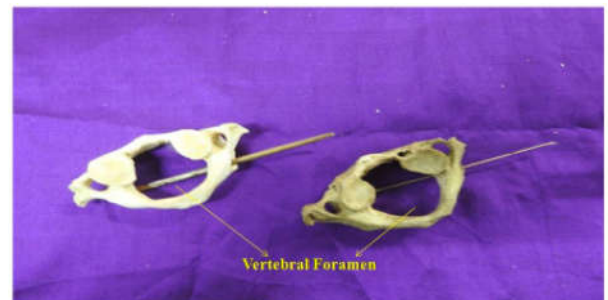

Fig. 5: Inferior View

Table 2: Incidence of Arcuate Foramen

Type of Variation	No of cases	Incidence %
Arcuate Foramen (unilateral) on left side	02	0.95
Arcuate Foramen (unilateral) on right side	00	00
Arcuate Foramen (bilateral)	00	00

One axis bone presented with an elongated projection on odontoid process [Figure 6a & 6b] & [Table 3]

Elongated Bony Projection on Odontoid Process

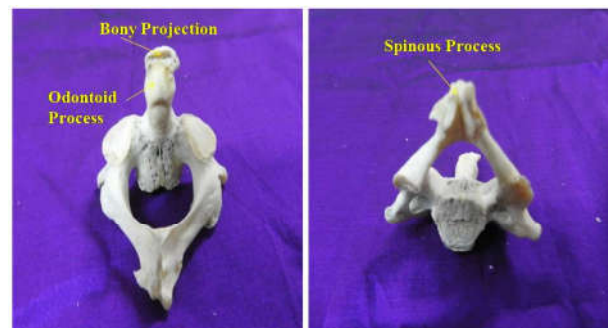


Fig. 6a: Postero-superior View

Fig.6b: Inferior View

Table 3: Incidence of Elongated bony projection on Odontoid process

Type of Variation	No of cases	Incidence%
Elongated bony projection on odontoid process	01	0.48

The occurrence of assymetrical foramen transversarium was seen in one typical cervical vertebra.[Figure 7a & 7b] & [Table 4]

Asymmetrical Foramen Transversarium

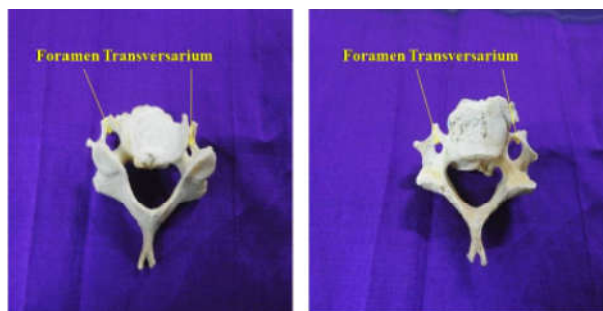


Fig. 7a: Superior View **Fig. 7b:** Inferior View

Double Foramen Transversarium

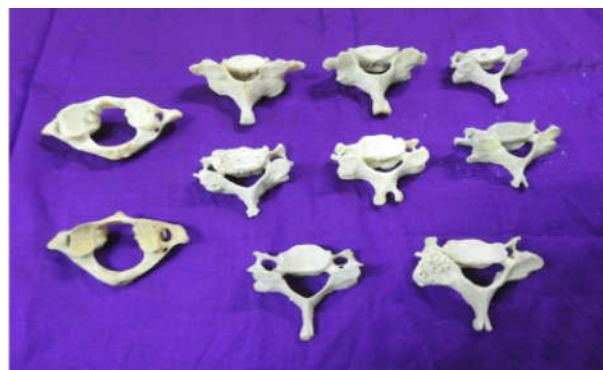

Fig. 8:

Bilateral Double Foramen Transversarium

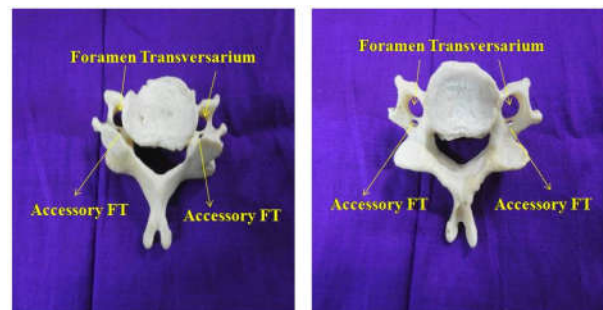


Fig. 9a: Superior View **Fig. 9b:** Inferior View

The occurrence of double foramen transversarium was seen in five bones bilaterally and in five bones unilaterally. The double foramen transversarium bilaterally present in four typical cervical vertebrae

and one atlas, whereas unilaterally present in four typical cervical vertebrae and one atlas, all were present unilaterally on the right side [Figure 8,9 &10] & [Table 5]

Unilateral Double Foramen Transversarium

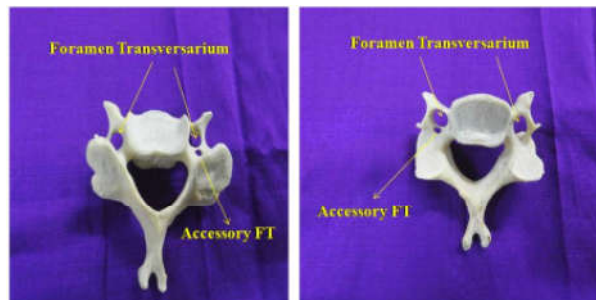


Fig. 10a: Superior View **Fig. 10b:** Inferior View

Table 5: Incidence of Double Foramen Transversarium

Type of Variation	No of cases	Incidence%
Double Foramen Transversarium (bilateral)	05	2.38
Double Foramen Transversarium (unilateral) on right side	05	2.38
Double Foramen Transversarium (unilateral) on left side	00	00

Discussion

Fused cervical vertebrae is also considered as Block vertebrae. The Orthodontist will usually be the first ones to identify cervical abnormalities as they are asymptomatic until adolescence or young adulthood. The congenital fusion of second cervical vertebra axis with the third cervical vertebrae will limit the movements taking place between these bones and therefore third cervical vertebra is known as "Vertebrae Critica" by Cave. This anomaly may be asymptomatic, however it may also present with manifestation of serious clinical features such as Myelopathy and also may be associated with syndromes such as Klippel-feil & Crouzon's syndrome. Fused cervical vertebrae results in limitation of neck movements, muscular weakness, atrophy and morphological sensory loss [3].

Location of Block Vertebrae in order of frequency are cervical spine (C2,3 and C5,6), lumbar spine (L4,5) and any sections of thoracic spine [4].

Vertebral fusion anomalies are likely to be associated with disturbance of pax-1 gene expression in the developing vertebral column [5].

Defects in the development of occipital and cervical somites and effect of environment, genetic factors during third week of conception may lead to

such fusion of vertebra [6].

Vertebral column starts developing during third week with segmentation of paraxial mesoderm forming somites. Failure of normal segmentation of embryological spines may lead to fused vertebra/ block vertebra. If congenital, it can be one of the primary malformation of chorda dorsalis [7].

If acquired, it's usually associated with serious diseases such as juvenile rheumatoid arthritis, tuberculosis and trauma. Incidental radiographic findings helps in the early diagnosis of fused cervical vertebrae [8].

Arcuate foramen is a foramen or canal present when sulcus arteriae vertebralis which is situated on the cranial surface of posterior arch of atlas occasionally gets converted into foramen by a bony bridge [9].

First description of of arcuate foramen was done by Kimmerle in the year 1930. Arcuate foramen has many other names like kimmerle's anomaly/ foramen atlantoideum/foramen retroarticulare superior/ponticulus posterior of atlas. It is usually associated with chronic tension type headaches and neurosensory type hearing loss [10].

Arcuate foramen is classified into three groups depending upon complete or incomplete ossification of the ligaments

- I Represents retroarticular impression on posterior arch of atlas
- II Defined retroarticular sulcus
- III Complete bony ring [11].

Arcuate foramen is associated with Barie-Lieou syndrome which presents with headache, retroorbital pain, vasomotor disturbance of face, disturbance of vision, swallowing and phonation [12].

Elongated Bony projection on odontoid process occurs as a result of calcification of the ligaments attached to dens. It usually develops as a result of inflammatory disease/ traumatic injury especially in elderly [13].

The various odontoid anomalies are Os Odontoideum, posteriorly inclined odontoid, Os terminale, odontoid hypoplasia, odontoid aplasia, odontoid duplication and anteverted odontoid [14].

Calcium deposition around odontoid process results in crowned dens syndrome where in patients presents with neck pain and increased body temperature. It can be misdiagnosed as polymyalgia rheumatica, giant cell arteritis, meningitis or spondylitis [15].

Assymetrical Foramen transversarium results due to tortuosity of vertebral artery, which may cause bone destruction and hence may be a factor determining the size of foramen transversarium and asymmetry in size of foramen transversarium [16]

Impingement of osteophytes from uncinat process and articular process of cervical vertebrae is also responsible for narrowing of foramen transversarium and compression of vertebral artery or irritation of surrounding sympathetic plexus [17]

Double foramen transversarium occurs due to variations in the vertebral vessels which will be manifested in the changes of foramen transversarium as vertebral vessels play a key role in the formation of foramen transversarium. In contrast, variations of foramen transversarium can be useful in estimating the variations of vessels [18].

If foramen transversarium is divided by fibrous/ bony bridge, separating the artery and vein, the smaller posterior part encloses a branch of nerve and vertebral vein which forms the accessory vertebral foramen [19].

Variations of foramen transversarium causes vertebrobasilar insufficiency as a result of neck movements, may also result in headache, migraine and fainting attacks [20].

Double foramen transversarium is also correlated with duplicate vertebral artery, bifid/duplicate origin and fenestration of vertebral artery [21].

Conclusion

In the present study the following variations of the cervical vertebrae were observed

Fused cervical vertebrae-0.95%

Arcuate foramen-0.95 %

Elongated bony projection -0.48%

Assymetrical foramen transversarium-0.48%

Double foramen transversarium-bilateral-2.38%

Double foramen transversarium-unilateral on right side-2.38%

Double foramen transversarium-unilateral on left side-0%

These variations are noteworthy to neurosurgeons, orthopaedicians, surgeons, spine surgeons and radiologists. Knowledge of such anomalies is important for anaesthesiologists also during endotracheal intubation.

References

1. Susan Standring, Harold Ellis, Jeremiah C Healy, David Jonson, Andrew Williams; Gray's Anatomy. The Anatomical basis of clinical practice; 39th edn; Elsevier Churchill livingstone; 2008;742-746
2. M Y Dofe, A D kasote, M M Meshram. The study of cervical vertebrae showing variational presentation of foramen transversarium. *Int J Anat Res.* 2015; 3(2):1128-32.
3. Dunsker SB, Brown O, Thompson N. Craniovertebral anomalies. *Journal of Clinical Neurosurgery.* 1980;27:430-33.
4. David KM ,Coop AJ, Stevens JM, Hayward RD, Crockard HA. Split cervical spinal cord with Klippel-Feil syndrome: seven cases. *Journal of Neurology.* 1996;119(6):1859-72.
5. Moore KL, Persaud TVN. The skeletal system; The developing Human: clinically oriented embryology. 8th edition; 2008.pp.339,344
6. Bock vertebra; <http://www.e-radiography.net/radpath/b/blockvertebra.htm>.
7. Cave AJE. *Journal of Anatomical Society London.* (Proceedings anatomical society). 1937 Oct;72:319.
8. Erdil H, Yidiz N, Cimen M. Congenital fusion of cervical vertebrae and it's clinical significance. *Journal of Anatomical society of India.* 2003;52(2):125-27.
9. T Glenn Pait, M.D, Kenan. I. Arnautovic, M.D and Luis A.B. Borba M.D. The Anatomy of the Atlantoaxial Complex; *Neurological Surgery. Anatomical Perspectives.* 1997;7:91-98.
10. Michael J Huang, and John A Glaser. Complete arcuate foramen precluding C1 lateral mass screw fixation in a patient with rheumatoid arthritis; case report; *Iowa orthop;* 2003;23:96-99.
11. Erdogan Unur, Nuri Erdogan, Harun Ulger, Nihat Ekinci, Omer Ozturk. Radiographic incidence of complete arcuate foramen in turkish population; *Erciyes Medical.* 2004;26(2);50-54.
12. CA Limousin. Foramen arcuale and syndrome of barre-lieou; *International Orthopaedics.* 1980;4:47-49.
13. KB Sim and JK Parkb. A Nodular Calcification of the Alar ligament Simulating a fracture in the Craniovertebral Junction. *AJNR.* 2006 Oct 27:1962-1963
14. A Aouba, V Vuillemin Bodaghi, C Mutschler and M De Bandt. Crowned dens syndrome misdiagnosed as polymyalgia rheumatica, giant cell arteritis, meningitis or spondylitis:an analysis of eight cases. *Rheumatology.* 2004;43(12):1508-1512
15. Stevens JM, Chong WK, Barber C, Kendall BE, Crockard HA. A new appraisal of abnormalities of odontoid process associated with atlanto-axial subluxation & neurological disability. *Brain* 1994;117:133-48
16. Serdar Kaya, Nalan Damla Yilmaz, Serhat Pusat, Cahit Kural, Alpaslan Kirik et al. Double Foramen Transversarium Variation in Ancient Byzantine Cervical Vertebrae: Preliminary Report of an Anthropological Study. *Turkish Neurosurgery.* 2011;21(4):534-38.
17. Kovac A. Subluxation deformation of cervical apophyseal joint. A contribution to the etiology of headache. *Acta Radiologica.* 1955;43:1-16
18. Divya Agarwal, Biswa Bhusan Mohanty, Sunita Sethy, Bijaylaxmi Parija, Santhosh Kumar Hazary et al. Variations in foramen transversarium: An osteological study in eastern India. *International Journal of Current Research.* 2012 Sep;4(9):120-122.
19. Apurba Patra, Harsimarjit Kaur,Usha chhabra, Subhash Kaushal, Upasana Kumar Double foramen transversarium in dried cervical vertebra: An osteological study with it's clinical implications. *Indian Journal Oral Sci.* 2015;6:7-9
20. Chaudhari ML, Maheria PB, Bachuwar. Double foramen transversarium in cervical vertebra: Morphology and Clinical importance. *Indian Journal of Basic & Applied Medical Reasearch;* 2013 Sep;8(2):1084-88.
21. Hashimoto H, Onishi H, Yuasa T, Kawaguchi S. Duplicate origin of vertebral artery: report of two cases. *Neuroradiology.* 1987;29:301-03.

.....

Instructions to Authors

Submission to the journal must comply with the Guidelines for Authors.
Non-compliant submission will be returned to the author for correction.

To access the online submission system and for the most up-to-date version of the Guide for Authors please visit:

<http://www.rfppl.co.in>

Technical problems or general questions on publishing with IJA are supported by Red Flower Publication Pvt. Ltd's Author Support team (http://rfppl.co.in/article_submission_system.php?mid=5#)

Alternatively, please contact the Journal's Editorial Office for further assistance.

Editorial Manager
Red Flower Publication Pvt. Ltd.
48/41-42, DSIDC, Pocket-II
Mayur Vihar Phase-I
Delhi - 110 091(India)
Mobile: 9821671871, Phone: 91-11-22754205, 45796900, 22756995
E-mail: author@rfppl.co.in

Estimation of Stature from Cephalo-Facial Dimensions: A Cross Sectional Study in Central India

Monali Hiwarkar¹, Anjali Prasad², Onjal Taywade³

Abstract

Introduction: Highly decomposed, mutilated & dismembered body parts like skull or facial remains are often brought for the medico-legal examination. Under such circumstances, cephalo-facial parameters are crucial in establishing the identity of the deceased. **Aim:** Estimation of stature from cephalo-facial measurements like horizontal head circumference, morphological facial length and bigonial diameter and to derive regression formulae to estimate stature in central India population. To find coefficient of correlation between stature & different cephalo-facial measurements. **Material and Methods:** A cross sectional study comprised of total 300 healthy students (187 Females and 113 Males) in the age range 18-23 years were included. The subjects were studied for the parameters- height (stature), horizontal head circumference, morphological facial length, bigonial diameter. **Results:** The average stature of male & female were found to be 171.33 & 157.34 cm respectively with range of 149 to 193 in males & 144.6 to 171.2 in females. We found weak correlation between stature and cephalo-facial measurements in males as well as female subjects. Though the correlation was weak it was significant and higher in females as compared to males. **Conclusion:** This study suggests that stature could be estimated using cephalo-facial measurements like horizontal head circumference, morphological facial length, bigonial length etc. The mean values for males were higher than those of females. However the correlation was weak and need to be validated on larger population.

Keywords: Stature; Horizontal Head Circumference; Morphological Facial Length; Bigonial Diameter.

How to cite this article:

Monali Hiwarkar, Anjali Prasad, Onjal Taywade. Estimation of Stature from Cephalo: Facial Dimensions: A Cross Sectional Study in Central India. Indian J Anat. 2019;8(2):91-94.

Introduction

Anthropometry is the science of obtaining systematic measurements of human body. Stature represents the length of the body in standing position from head to foot; which is one such important parameter that helps in personal identification [1]. It has a definite & proportional biologic relationship with each & every part of

our body like head, face, trunk & extremities [2]. The estimation of height from measurements of different body parts has always attracted interest of anatomists, anthropologists and forensic experts as well. It has important application in medico-legal as well as forensic examination, especially during natural calamities, mass disaster, surgery & biomedical engineering [1-3].

For medico- legal examination often highly decomposed, mutilated & dismembered body parts are presented to forensic expert. Sometimes only skull or facial remains are brought for such examination. Under such circumstances, cephalo – facial parameters are crucial in establishing the identity of the deceased [3]. During embryonic life the skeletal elements develop through two different embryonic processes. The enchondral ossification gives rise to facial bones, vertebrae, long bones & lateral part of clavicles. The intramembranous ossification gives rise to flat bones of cranium and medial clavicles.

Author's Affiliation: ¹Assistant Professor ²Associate Professor, Department of Anatomy, Index Medical College, Hospital & Research Center, Indore, Madhya Pradesh 452001, India. ³Assistant Professor, Department of Biochemistry, MGM Medical College, Indore, Madhya Pradesh 452001, India.

Corresponding Author: Anjali Prasad, Associate Professor, Department of Anatomy, Index Medical College, Hospital & Research Center, Indore, Madhya Pradesh 452001, India.

E-mail: anjaliPrasad28@gmail.com

Received 27.03.2019 | Accepted 24.04.2019

Many studies have been conducted on the determination of stature from percutaneous measurements of various body parts including arms, legs, feet, hands, etc. [4-10] and establishment of such anthropometric data bank is essential to determine one's stature, age, sex & race etc.

The studies conducted on cephalo-facial measurements to estimate the stature are limited. Hence, the present research project was designed to study the correlation of stature with cephalo - facial measurements & to derive regression formulas for determining the stature.

Objectives

To find correlation between stature & different cephalo-facial measurements. To derive regression formulae to estimate stature from horizontal head circumference (HCC), morphological facial length (MFL) and bigonial diameter (BD).

Material and Methods

The present study was a cross sectional study comprised of total 300 healthy students after getting ethical clearance from institution. 187 females and 113 males students in the age group 18-23 years, of first year medical faculties (MBBS, BDS, BPT) at Index Medical College, Indore. During this age, height remains more or less static.

Those having any obvious congenital physical abnormality, history of any facial surgical procedures, old fractures, metabolic or developmental disorders or any significant disease which could have affected the general or bony growth were excluded from the study.

The subjects were studied for the following parameters.

1. Height (Stature)
2. Horizontal Head Circumference
3. Morphological Facial Length.
4. Bignonial Diameter

All the measurements were taken three times and the mean was taken to minimize subjective errors. The measurements were always taken at a fixed time, between 3-5 pm, to eliminate discrepancies of diurnal variation and by the same person to avoid error in methodology.

The instruments used in the study were

1. Stadiometer
2. Spreading caliper

All the measurements were taken using standard anthropometric instruments in centimeter to the nearest millimeter.

Measurement of Stature

Stature (height) is a measure of vertical distance from vertex to floor where Vertex is the highest point on the head in the mid-sagittal plane, when the head is held erectly or in Frankfurt's plane. Height was measured from vertex to floor by stadiometer with subject standing barefooted, erect on an even floor, in the Frankfurt's plane, passing through the lowest points on the infra-orbital margins and the tragion (the notch immediately above the tragus of the ear). The distance was measured from the highest point on the subjects head to the ground [11].

Measurement of Horizontal Circumference of Head

It is the maximum circumference of the head, usually horizontal just above the eyebrow ridges, measured from just above the glabella area to the area near the top of the occipital bone (opisthocranium). It was measured with the help of measuring tape [12].

Morphological Facial Length

It is the straight distance from gnathion to the nasion. Nasion is the median point at which a horizontal tangential to the highest points on the superior palpebral sulci intersects the mid sagittal plane when the subject is looking straight ahead. Gnathion is the lowest point on the lower border of mandible in the mid sagittal plane. It was measured with the help of sliding calliper [3].

Bignonial Diameter

It measures the straight distance between the two gonion, rounded postero-inferior corner of the mandible between ramus and the body. It was measured with the help of Spreading caliper [11].

The data collected was subjected to statistics to get mean, standard deviation, Pearson's correlation coefficient, regression analysis etc. using SPSS software (version 20).

Results

The data from this study was first analyzed for normality. Pearson's correlation (r) between stature & cephalo facial measurements was estimated. Regression equations for estimating height (Ht)

from cephalo-facial measurements along with standard error of estimates were derived.

& range of stature & different cephalo-facial measurements in male was higher than that of female subjects.

Form Table 1 & 2 it is clear that the mean, SD

Table 1: Summary of stature & cephalo-facial measurements

n=300	Age	Stature/Height	HHC	FL	BD
Mean	19.84	162.61	54.77	9.8	9.35
SEM	0.07	0.52	0.12	0.04	0.04
Median	20	161.3	54.5	9.8	9.2
SD	1.18	9.02	2	0.71	0.75
Range	8	48.4	11.5	4.5	3.7
Min	17	144.6	50	8	8
Max	25	193	61.5	12.5	11.7

SEM-Std error of mean, SD- Std deviation.

Table 2: Gender specific findings of stature & cephalo-facial measurements

Mean (SD)	Age	Height	HHC	FL	BD
Females 187	19.71 (1.18)	157.34 (5.31)	53.77 (1.40)	9.57(0.64)	9.05(0.60)
Males 113	20.05 (1.16)	171.33 (6.89)	56.42 (1.73)	10.16(0.68)	9.85(0.72)

Table 3: Pearson’s correlation (r) between stature & cephalo-facial measurements

Parameters	r- value (significance) males	r- value (significance) females
HHC	0.191 (0.043)	0.324 (<0.001)
FL	0.313 (0.001)	0.309 (<0.001)
BD	0.248 (0.008)	0.281 (<0.001)

Table 4: Regression equations for estimating height (Ht) from cephalo-facial measurements along with std error of estimates (SEE)

Parameter	Regression Equation (n=300)	SEE	Regression Equation (males)	SEE	Regression Equation (females)	SEE
HHC	Ht= 15.57 + 2.7x HHC	7.49	Ht= 128.47+ 0.76xHHC	6.78	Ht= 91.56 + 1.22xHHC	5.03
FL	Ht= 101.92 + 6.3x FL	8.13	Ht=138.99 + 3.18xFL	6.56	Ht= 132.75+ 2.56xFL	5.06
BD	Ht= 103.86 + 6.44xBD	7.89	Ht= 147.80+ 2.38xBD	6.70	Ht= 134.72+ 2.56xBD	5.11

Table 5. Comparison of correlation coefficient (between stature & different cephalo-facial parameters) from previous studies.

Sr. No.	Author Name	Gender	HHC	MFL	BD
1	Kalia et al. [13]	Male	0.14*	-	-
2	Krishan Kumar [14]	Male	0.773*	0.345*	0.449*
3	Krishan [2]	Male	0.781*	0.455*	0.462*
4	Mahesh Kumar [15]	Male	0.122*	0.177*	0.164*
		Female	0.181*	0.150*	0.119*
5	Agnihotri et al. [12]	Male	0.494	0.328	0.022
		Female	0.375*	0.164	0.159
6	Datta S [3]	Male	-	0.2721	-
		Female	-	0.1669	-
7	Present study	Male	0.191*	0.313*	0.248*
		Female	0.324*	0.309*	0.281*

*- Results are statistically significant.

Table 6: Comparison of regression equations of height with published data.

Sr No	Author Name	Population	Sample Size	HHC	MFL	BD
1.	Kewal Krishan [14]	Gujjars	996 M	Ht= 65.156 + 2.034 (HHC)	Ht= 121.869 + 4.618 (MFL)	Ht= 109.991 + 6.483 (BD)
2.	Mahesh Kumar [15]	Haryana	400-M 400-F	Ht= 126.57 + 0.523 (HHC)	Ht= 147.62 + 0.740 (MFL)	Ht= 147.61 + 0.733 (BD)
3.	Jibon kumar [16]	Naga of Manipur	199 M	-	-	Ht= 107.004 + 3.913 (BD)
4.	Thoudam [17]	Manipur Muslims	200-M	-	Ht= 128.206 + 2.989 (MFL)	-
5.	Shah [11]	Gujarati	676-M 225-F	-	Ht= 147.413 + 1.418 (MFL)	Ht= 150.804 + 1.01 (BD)
6.	Present Study	Madhya Pradesh	113-M 187-F	Ht= 128.47 + 0.76 HHC Ht= 91.56 + 1.22 HHC	Ht= 138.99 + 3.18 x MFL Ht= 132.75 + 2.56 x MFL	Ht= 147.80 + 2.38 x BG Ht= 134.72 + 2.56 x BG

Conclusion

This study suggests that stature can be estimated from cephalo-facial measurements like, horizontal head circumference, morphological facial length, bigonial diameter etc. Though the correlation was weak it was more significant in females. The regression equations for estimation of stature can be used on specified population or region. However, these equations need to be validated on larger population before using for medico-legal purpose.

References

- Mounika S, Yuvraj Babu K. Estimation of Stature from facial width. *J. Pharm. Sci. & Res.* 2015;7(6):353-54.
- Krishan K. Estimation of Stature from Cephalo-facial anthropometry in north Indian population. *Forensic Science international.* 2008;181:52.e1- 52.e6.
- Datta S, Sawant VG. Correlation of Stature with facial measurements of Maharashtra Adults *Indian Journal of Basic and Applied Medical Research.* 2017 March;6(2):305-11.
- Singh IP, Bhasin MK. *A Manual of Biological Anthropology.* New Delhi. Kamla Raj Enterprises; 2004:560.
- Chiba M, Terazawa K. Estimation of stature from somatometry of skull. *Forensic SciInt.* 1998;97:87-92
- Ozaslan A, Iscan MY, et al. Estimation of stature from body parts. *Forensic SciInt.* 2003;132(1):40e5.
- Krishan K. Anthropometry in Forensic Medicine and Forensic Science-'Forensic Anthropometry'. *Int. J. Foren. Sci.* 2007;2:1
- Santosh K, Garg R et al. Prediction of stature by the measurement of head length in population of Rajasthan, *Journal of Evolution of Medical and Dental Sciences.* 2013 April 8;2(4):1334-9.
- Pelin C, Zagyapan R, et al. Body height estimation from head and face dimensions: a different method. *J Forensic Sci.* 2010.
- Singh SJ, Neeta RK, Singh HV. Estimation of stature from different facial measurements among Lois of Phayeng village, Manipur. *J Medico legal Soc. Manipur.* 2006;1:22-6.
- Shah T, Patel MN, et al, Estimation of Stature from Cephalo-Facial dimensions by regression analysis *Journal of Indian Acad Forensic Med.* 2015 Jul-Sep;37(3):253-57.
- Agnihotri AK, Kachhwaha S, et al. Estimation of stature from cephalo-facial dimensions by regression analysis in Indo-Mauritian population, *Journal of Forensic and Legal Medicine.* 2011;18: 167-172.
- Kalia S, Shetty SK, et al. Stature estimation using odontometry and skull anthropometry. *Indian J Dent Res.* 2008;19(2):150-4.
- Krishan K, Kumar R. Determination of stature from cephalo-facial dimensions in a North Indian Population. *Leg med.* 2007 May;9(3):128-33.
- Mahesh Kumar, Patnaik VV et al. Estimation of stature from cephalo-facial anthropometry in 800 Haryanvi Adults. *Int. J. of plant, animal and environmental sciences.* 2013;3:42-6.
- Jibonkumar, Lilin Chandra, Estimation of Stature Using Different Facial Measurements Among the Kabui Naga of Imphal Valley, Manipur, *The Anthropologist.* 2006;8(1):1-3.
- Thoudam BD, Soibam JS. Estimation of stature from cephalometric measurements among male Muslims of Manipur, India. *International Journal of Research in Medical Sciences.* 2017 Sep;5(9):4055.

Correlation of Human Height with Foot Dimensions: A Study in Young Population of Central India

Sundip Charmode Hemant¹, Pujari Dinanath Keshavbhat², Kadlimatti Huchchesha shivappa³

Abstract

Background and Objective: Identification of sex, age, race and stature is the most important aspect of investigations in cases of mass disasters. Hand and foot dimensions has a strong correlation with stature and if either of the measurements is known, the other can be calculated. With this objective, the present study was proposed to correlate the foot dimensions with stature of an individual. **Methodology:** This cross-sectional study was conducted amongst 1000 participants (500 male and 500 female) of ESIC Institute Gulbarga over a period of 14 months. Foot length, foot breadth along with stature was measured. **Results:** Mean stature was 161.88. Mean Foot length on Right side was 24.34 cm and Mean Foot length on left side was 24.32 cm. Mean Foot Breadth on Right side was 8.95 cm and Mean Foot Breadth on left side was 8.96 cm. Linear Regression coefficient was calculated. Interpretation and **Conclusions:** Highly significant difference in right and left side mean foot length and breadth measurements was observed. Also observed was a strong positive statistically significant correlation between height and foot dimensions. This data could be useful for forensic, epidemiological and anthropometric studies where stature determination is of utmost importance.

Keywords: Correlation; Foot Length; Foot Breadth; Human Stature; Linear Regression Coefficient.

How to cite this article:

Sundip Charmode Hemant, Pujari Dinanath Keshavbhat, Kadlimatti Huchchesha shivappa. Correlation of Human Height with Foot Dimensions: A Study in Young Population of Central India. Indian J Anat. 2019;8(2):95-100.

Introduction

Many studies in the past have studied the importance of measuring the hand and foot dimensions to estimate stature. The hand and foot dimensions, being genetically derived varies in different races and ethnic groups and is used to determine sex, age, stature and nutritional status of an individual.

Identification of sex, age, race and stature are the most important aspect of investigations in cases of mass disasters like Bomb explosions, public vehicle

(plane, railway, bus, truck, car) accidents, cross border terrorist attacks, natural calamities, murders where bodies or isolated extremities are found in disintegrated, mutilated and skeletonized state [1-2].

Hand and Foot dimensions have been found to have a correlation with the stature of an individual. There is a strong correlation between stature and foot dimensions and if either of the measurements is known, the other can be calculated. With this objective, the present study was designed to correlate the Foot dimensions with Stature of an individual and to record the standard deviation in the estimation of Stature.

Aim

To study the relationship between foot dimensions with human stature.

Materials and Methods

Study design: Descriptive cross sectional study

Author's Affiliation: ¹Assistant Professor ²Associate Professor ³Professor and Head, Dept. of Anatomy, ESIC Medical College, Gulbarga, Sedam Road, Kalaburagi, Karnataka 585106, India.

Corresponding Author: Pujari Dinanath Keshavbhat, Associate Professor, Dept. of Anatomy, ESIC Medical College Gulbarga, Sedam Road, Kalaburagi, Karnataka 585106, India.

E-mail: drdinanath1971@gmail.com

Received 08.03.2019 | **Accepted** 16.04.2019

Setting: Department of Anatomy, ESIC Medical College and Hospital, Gulbarga, Karnataka.

Duration of study: 14 months; From 31st October 2017 to 31st December 2018.

Sample size: 1000 participants including Medical, Dental and Nursing students aged between 17 and 20 years of age in ESIC Institute, Gulbarga.

Sampling technique

Inclusion criteria: Medical, Dental and Nursing students aged between 17 and 20 years in ESIC Institute, Gulbarga.

Exclusion criteria

Students of NRI quota and students those with poorly defined wrist creases, deformities of vertebral column & limbs, contractures, missing limbs, history of trauma to hand and foot, with features suggestive of dysmorphic syndromes, chronic illness, hormonal therapy were excluded from the study [3-4].

Sample selection

Simple random sampling method [5] was used to select 1000 Medical, Dental and Nursing students out of total 3000 students in ESIC Institute Gulbarga satisfying the inclusion criteria. These subjects belonged to 1st to 3rd year, hence were easily accessible and also represented the young adult age group.

Data collection procedure

Foot Length: Each subject was made to stand on a Calibrated Foot Board with his/her back against the wall in such a manner that the posterior most point of the heel would gently touch the wall. A vertical stop was placed against the anterior most point of the foot. The distance between the posterior most point of the heel and the anterior most point of the foot was measured as the foot length. (Anitha Oommen et al. [6], 2005).

Foot Breadth: It was be measured as distance between Metatarsal tibiale (point projecting most medially on the head of the 1st metatarsal bone) and Metatarsal Fibulare (point projecting most laterally on the head of the 5th metatarsal bone) (Rati Tandon et al. [7], 2016)

Height: Standing height was measured to the nearest centimeters (cm) using a Stadiometer with

subject standing erect on a horizontal resting plane bare footed having the palms of the hands turned inward and the finger pointing downwards. The height was measured from the sole of the feet to the vertex of the head as recommended by International Biological Program. (A. Ibegbu, David et al, [8], 2013)

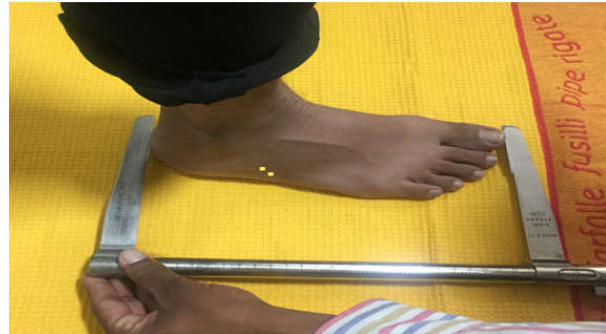

Fig 1: Foot length measured as distance between the posterior most point of the heel and the anterior most point of the foot

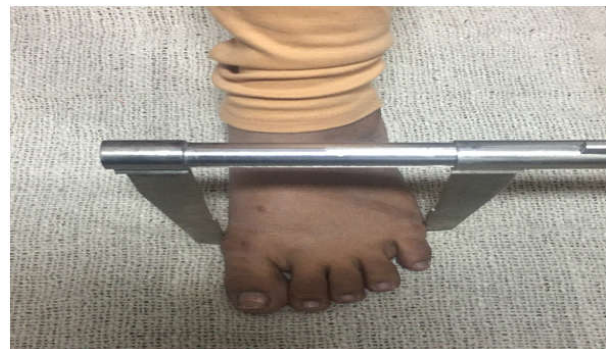

Fig 2: Measured as distance between point projecting most medially on the head of the 1st metatarsal bone and point projecting most laterally on the head of the 5th metatarsal bone.

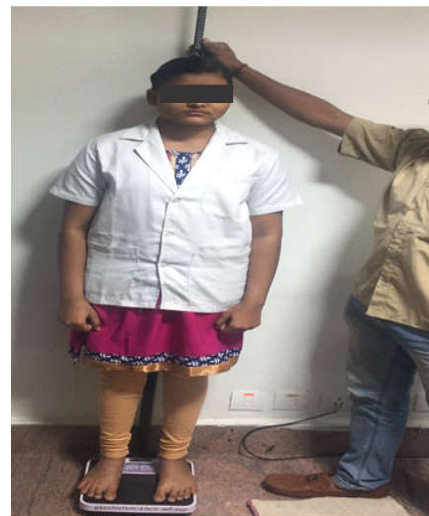

Fig 3: Measurement of height was from the sole of the feet to the vertex of the head

Data collection tools: Vernier slide calipers, Calibrated foot board, Stadiometer, Regular weight

machine, Questionnaire for collection of personal details, academic scores, Lead pencils, stationary etc. Data collected were tabulated, graphically represented and statistically analyzed.

Results

Statistically highly significant positive correlation was observed between Height and Foot length of both sides (p<0.01). Table 1 reveals that, foot length of both sides was also significantly more amongst those having more height.

Statistically highly significant positive correlation was observed between Height and Foot breadth of both sides (p<0.01). Table 2 reveals that, foot breadth of right or left side was significantly more in those participants whose height was more.

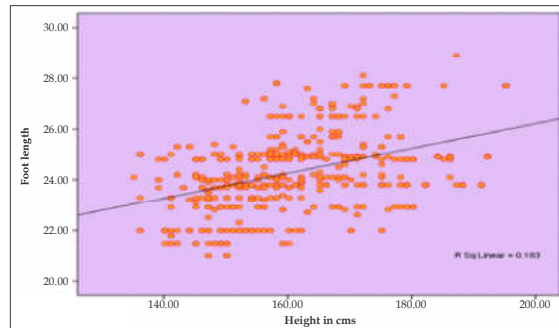
There is statistically very highly significant difference in Foot length, Foot breadth and Height among males and females (p<0.001). Foot length, Foot breadth on both sides and Height was found significantly more in males compared to females.

Table 1: Correlation of Foot length and stature

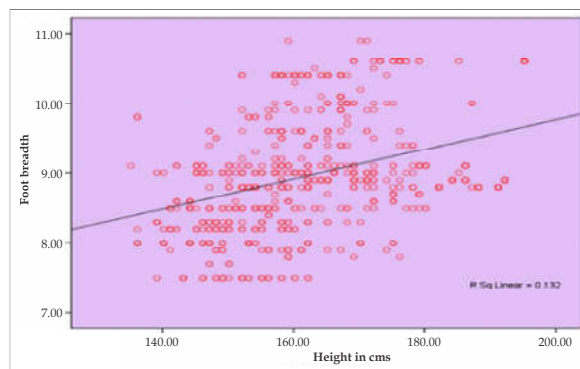
Variables	Minimum	Maximum	Range	Mean	SD	N	Correlation r	p value
Height (cm)	135.2	195.2	60.0	161.88	13.45	1000	--	--
Foot length right (cm)	21.0	28.9	7.9	24.34	1.54	1000	r = 0.428	p<0.01 HS
Foot length left (cm)	21.5	29.0	7.5	24.32	1.50	1000	r = 0.516	p<0.01 HS
Linear Regression Equation	Height = 71.391 + 4.782 (Foot length right)							
Linear Regression Equation	Height = 49.706 + 4.786 (Foot length left)							

Table 2: Correlation of Foot breadth and stature

Variables	Minimum	Maximum	Range	Mean	SD	N	Correlation r	p value
Height (cm)	135.2	195.2	60.0	161.88	13.45	1000	--	--
Foot length right (cm)	7.5	10.9	3.4	8.95	0.78	1000	r = 0.364	p<0.01 HS
Foot length left (cm)	7.7	11.5	3.8	8.96	0.68	1000	r = 0.367	p<0.01 HS
Linear Regression Equation	Height = 106.01 + 6.240 (Foot breadth right)							
Linear Regression Equation	Height = 96.843 + 7.253 (Foot breadth left)							



Graph 1: Correlation between Foot length and Stature

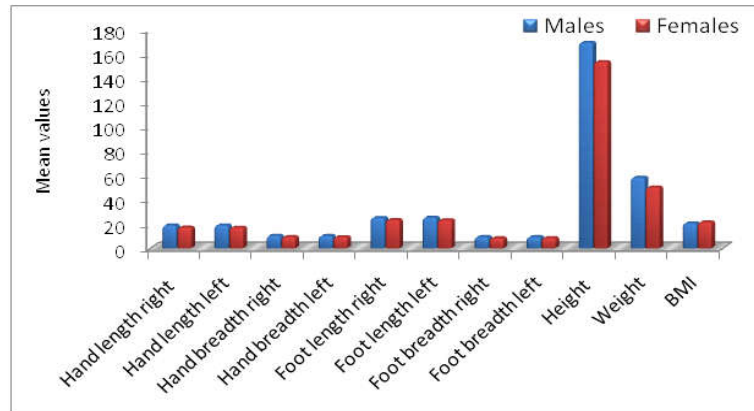


Graph 2: Correlation between Foot breadth and Stature

Table 3: Gender wise comparison of parameters

Variables	Male (N=500)	Female (N=500)	Z test value	p value and significance
	Mean \pm SD	Mean \pm SD		
Foot length right	25.18 \pm 1.32	23.39 \pm 1.19	Z = 30.07	p<0.001, VHS
Foot length left	25.31 \pm 1.16	23.19 \pm 0.96	Z = 31.19	p<0.001, VHS
Foot breadth right	9.39 \pm 0.71	8.45 \pm 0.52	Z = 22.97	p<0.001, VHS
Foot breadth left	9.35 \pm 0.59	8.52 \pm 0.47	Z = 23.21	p<0.001, VHS
Height	169.28 \pm 11.75	153.42 \pm 9.75	Z = 22.26	p<0.001, VHS

NS= not significant, S=significant, HS=highly significant, VHS=very highly significant

**Graph 3:** Multiple bar diagram represents gender wise comparison of variables**Table 4:** Comparison of present study with previous studies:

Sl. no	Study/ Author/ Year	Sample size	Parameters studied	Mean height M/F	Observations			
					Mean foot length		Mean foot breadth	
					Right M/F	Left M/F	Right M/F	Left M/F
1	Anitha Oommen et al. [6] (2005)	100	HL, FL	NA	26.21 / 23.75	26.0 / 23.68	NM	NM
2	B Danborbo, A Elukpo et al. [1] (2007)	400	H, HL, HB, FL, FB	173.7 / 160.0	28.39/24.52	26.42 / 24.70	9.02 / 8.23	9.09/ 8.11
3	Patel SM, Shah GV et al. [11] 2007	502	H, FL	170.9 / 156.14	Male - 24.44	Female -22.34	NM	NM
4	Chikhalkar BG et al. [11] 0 (2008)	300	H, W, FAL, HL, HB, FL, FB	167.26	24.008 with SD 1.420	8.895 with SD 0.703		
5	Krishna K, Kanchan T et al. [12] (2011)	246	HL, HB, FL,FB	NA	NA	NA	NA	NA
6	Patel PN, Tanna JA et al. [2] (2012)	273	H, FL, FB, HL, HB, AS	164.59	24.178 with SD 1.809	9.28 with SD 0.865		
7	A. Ibegbu, David et al. [8] (2013)	600 children	H, HL	NC	NC	NC	NC	NC
8	Prakash M. Mohite et al. [9] (2015)	230	H, HL, HB, FL	165.02	Male - 25.86, Female - 22.67	NM	NM	
9	Uhrova P, Benus R et al. [13] (2015) - Slovak adults	250	H, HL, HB, FL, FB	NA	NA	NA	NA	NA
10	Rati Tandon et al. [7] (2016)	497	H, HL, HB, FL, FB, DL	172.7 / 157.1	Male - 26.22, Female - 23.35	Male - 9.95, female - 8.89		
11	Kim W, Kim YM et al. [14] (2018)	5195	H, HL, HB, FL, FB	NM	NA	NA	NA	NA
12	Present study (2018-19)	1000	H, FL,FB	161.88	25.18/23.39	25.31/23.19	9.39/8.45	9.35/8.52

H- Height, HL - Hand length, HB - Hand breadth, FL - Foot length, FB - Foot breadth, PL - Palm length, DL - Digit / finger length, AS-Arm span, FAL - Forearm length, NM - Not measured NC - Not comparable, NA - Not available.

Discussion

In present study, human stature ranged from 135.2 cm to 195.2 cm. mean stature was 161.88 cm with SD of 13.45. These findings correspond closely with studies done on Indian population like that of Patel et al. [2] (164.59 cm) and Mohite et al [9] (165.02 cm) and Chikhalkar et al. [10] (167.2 cm). (Table 4).

Foot length on right side ranged from 21.0 cm to 28.9 cm with Mean of 24.34 cm and SD of 1.54. Foot length on left side ranged from 21.5 cm to 29.0 cm with Mean of 24.32 cm and SD of 1.50. (Table 1). These findings correspond with studies of Anitha Oommen et al. [6], Rati Tandon et al. [7], Patel SM, Shah GV et al. [11] 2007, Prakash M. Mohite et al. [9] (2015) [Table 4].

Foot breadth on right side ranged from 7.5 cm to 10.9 cm with Mean of 8.95 cm and SD of 0.78. Foot breadth on left side ranged from 7.7 cm to 11.5 cm with Mean of 8.96 cm and SD of 0.68. (Table 2). These findings correspond with studies of B Danborn, A Elukpo et al. [1] (2007), Rati Tandon et al. [7], Patel PN, Tanna JA et al. [2] (2012), Chikhalkar BG et al. [10] (2008). [Table 4].

Gender wise correlation revealed statistically highly significant difference between males and females ($p < 0.001$) in foot dimensions on both sides and also in height (Table 3) and were higher in males as compared to females. These findings matched with studies of Chikhalkar BG, Mangaonkar AA et al. [10] (2008), Kavyashree AN et al. [11] (2015) and Prakash M. Mohite et al. [14] (2015). [Table 4].

Correlation coefficient 'r' derived in the study for foot length and height was right side $r = 0.428$, left side $r = 0.516$. Correlation coefficient 'r' for foot breadth and height was right side $r = 0.364$, left side $r = 0.367$. This corresponds well studies like B Danborn, A Elukpo et al. [1], 2007 (right foot length-Male- 0.58, Female - 0.61, left foot length - Male -0.61, Female - 0.40), Rati Tandon et al. [7] (foot length - 0.709, foot breadth - 0.497), Patel PN, Tanna JA et al. [2], 2012 (foot length - 0.767, foot breadth - 0.665), Chikhalkar BG et al. [10], 2008 (foot length - 0.6102, foot breadth - 0.4886). Uhrova P, Benus R et al. [13] (2015) showed highest correlation coefficient for foot length in males ($r=0.71$) as well as in females ($r=0.63$) which matched the finding of present study [Table 4].

Linear regression Equation derived in present study corresponds closely with that derived from

earlier studies done in Indian population like Rati Tandon et al. [7] (foot length - male: $y = 3.09 * FL + 91.46$, female: $y = 2.896 * FL + 89.55$; foot breadth - male: $y = 4.55 * FB + 127.39$, female: $y = 3.684 * FB + 124.4$), Chikhalkar BG et al. [10] (ht. = $79.72379 + 3.650632 * FL$, ht. = $114.828119 + 5.906901 * FB$), Prakash M. Mohite et al. [14] (Ht. = $64.81 + 0.42 * \text{Foot Length}$), Patel PN, Tanna JA et al. [2] (ht. = $70.37 + 3.8969 * FL$, ht. = $99.05 + 7.063 * FB$).

Conclusions

1. Highly significant difference was observed in mean foot length and breadth on both sides.
2. Positive statistically significant correlation was observed between height and foot dimensions.
3. The linear regression formula derived can be used for adult between 17-20 years but it might be of limited use for children and older people for measuring the stature and shoe design.
4. Equation derived from present study can be used to estimate stature from either of the feet dimensions and vice versa among the Central Indian population.
5. It would be unwise to use the same equations for stature estimation for different Indian populations.
6. Foot length showed the highest correlation coefficient for estimating the stature of an Individual as observed in our study.
7. The data collected should be useful for anthropologists and forensic experts.

Limitations

1. In the present study, age range of only 17 to 20 years was considered.
2. Only healthy individuals were included in the study. Hence the data may not be applicable students those with deformities of vertebral column & limbs, contractures, those with h/o of trauma to foot, those with features suggestive of dysmorphic disorder.
3. Applicability of anthropometric measurements in living & deceased individuals may practically differ.
4. The present study is a preliminary one & would be followed up by other studies to address the above limitations.

References

1. Danborn B, Elukpo A. Sexual Dimorphism in Hand and Foot length, Indices, Stature-ratio and relationship to Height in Nigerians. *The Internet Journal of Forensic Science*. 2007;3(1):1-5.
2. Patel PN, Tanna JA, Kalele SD. Correlation between Hand Length and various Anthropometric parameters. *International Journal of Medical Toxicology and Forensic Medicine*. 2012;2(2):61-63.
3. Rastogi P, Nagesh KR, Yoganarasimha K. Estimation of Stature from hand dimensions of North & South Indians. *Legal Medicine*. 2008;10(4):185-189.
4. Keshavachandran CN, Bihari V, Mathur N. The normal range of body mass index with high body fat percentage among male residents of Lucknow city in north India. *Indian J Med Res*. 2012;135(1):72-77.
5. Kothari CR, Garg G. *Research methodology- Methods and techniques*. Third edition 2014; Reprint 2016. Page 14.
6. Oommen A, Mainker A, Oommen T. A Study of the Correlation between Hand length and Foot length in humans. *J. Anat. Soc. India*. 2005;54(2):55-57.
7. Tandon R, Yunus SM, Faruqi NA, Asghar A. Measurements of Hand and Foot - A Predictor of Stature in Adult Human Population of Uttar Pradesh. *International Journal of Anatomy, Radiology and Surgery*. 2016;5(1):12-15.
8. Ibegbu AO, David ET, Hamman WO, Umana UE, Musa SA. Association of Hand Length with Height in Nigerian School Children. *Journal of Biology and Life Science*. 2013;4(2):83-94.
9. Mohite PM, Keche AS, Mohite DP, Keche HA. Correlation of the Dimensions of Hand & Feet with Stature of an Individual: A Study on Central Indian Adults. *J Indian Acad. Forensic Med*. 2015;37(2):160-164.
10. Chikhalkar BG, Mangaonkar AA, Nanandkar SD, Peddawat RG. Estimation of stature from measurements of long bones, hand and foot dimensions. *J Indian Acad Forensic Med*. 2009; 32(4):329-30.
11. Patel SM, Shah GV, Patel SV. Estimation of height from measurements of foot length in Gujarat region. *J Anatomy Soc India*. 2007;56(1):25-27.
12. Krishan K, Kanchan T, Sharma A. Sex determination from hand and foot dimensions in a North Indian population. *J Forensic Sci*. 2011;56(2):453-9.
13. Bodorikova S, Nescakova E. Estimation of stature using hand and foot dimensions in Slovak adults. *J. Forensic. Leg Med (Tokyo)*. 2015;17(2):92-7.
14. Kim W, Kim YM, Yun MH. Estimation of stature from hand and foot dimensions in a Korean population. *J Forensic Leg Med*. 2018;55:87-92.

.....

Morphological and Morphometric Study of Scaphoid Bone in South Coastal Population

Madala Venkateswara Rao¹, Lattupalli Hema²

Abstract

Background: Scaphoid is boat shaped bone and is the largest bone of proximal row more prone for fractures and has utmost surgical importance. **Aim and Objectives:** As this bone has some interesting features this bone was taken for study to observe the variants like, the Scaphoid waist, tubercle, width of dorsal sulcus length of Dorsal Sulcus, length of scaphoid, ridge for scl, sulcus for flexor carpi radialis, waist circumference, tubercle circumference, primary height of tubercle and secondary height of the tubercle. **Material and Methods:** The study included one hundred dry human scaphoid bones (50 left and 50 right) which were obtained from the department of anatomy, Narayana Medical College, Nellore, India. The morphometric parameters were measured with vernier caliper of 0.02 mm accuracy; the circumference was measured by placing a thread around them and measuring its length. A magnifying lens was used to observe the number of foramina. **Results:** The tubercle was present in all the scaphoid bones. Among the left scaphoid bones, 22 were of conical shape and 28 were pyramidal shape. Similarly 36 right scaphoid tubercles were of conical shape and 14 were of pyramidal shape. The waist was absent in 1 scaphoid of right side, rest of all the bones had waist. The dorsal sulcus was absent in 1 scaphoid of left side and 2 on the right side. The shape of scapholunate articular surface was noted as either half moon or crescentic shape. Among them, 38 scaphoids of left side had the shape of half moon and 12 were of crescentic. Similarly 36 of right side were of half moon and 14 were of crescentic. The shape and variations of the dorsal sulcus were noted. Most of the scaphoid had main (single) dorsal sulcus 63%. In contrast, 29% had two dorsal Sulci and 6% had a Y shaped sulcus. Foramina in the dorsal sulcus were counted, all the scaphoids had a minimum of one foramen in the main dorsal sulcus and 92% had more than one foramen. All scaphoids which presented with secondary sulci had a foramen in it. The ridges for the origin of scapholunate interosseous ligament were present in 41 scaphoids of left side and 40 of right side. Sulci of flexor carpi radialis were also seen and it was present in 38 scaphoids of left side and 42 of right side. **Conclusion:** The scaphoid fracture occurs in young healthy individuals and is the most commonly fractured bone of the wrist (50%-80% of all carpal bone injury). The complex shape of scaphoid and its orientation within the carpus makes the radiological interpretation of scaphoid anatomy difficult. The goals of reconstructive surgery for scaphoid fracture non unions include restoration of normal scaphoid length and shape by use of the contraletaral scaphoid bone as a geometric model.

Keywords: Morphological; Morphometric Study; Scaphoid bone.

How to cite this article:

Madala Venkateswara Rao & Lattupalli Hema. Morphological and Morphometric Study of Scaphoid Bone in South Coastal Population. Indian J Anat. 2019;8(2):101-106.

Introduction

The largest bone of the proximal carpal row is the Scaphoid bone. Scaphoid bone is otherwise called as scaphoideum, Navicular of the hand which can be distinguished because of its distinctive boat like shape as its name suggest (Greek scaphe = boat) [11], whose approximate shape and size is like a cashew nut [2]. It is situated between the hand and forearm on the thumb side of the wrist (also called

Author's Affiliation: ¹Assistant Professor ²Professor and Head, Department of Anatomy, Narayana Medical College, Chinthareddypalem, Nellore, Andhra Pradesh 524003, India.

Corresponding Author: Lattupalli Hema, Professor and Head, Department of Anatomy, Narayana Medical College, Chinthareddypalem, Nellore, Andhra Pradesh 524003, India.

E-mail: hemakarra06@gmail.com

Received 31.01.2019 | **Accepted** 06.03.2019

the lateral or radial side), which forms the radial border of the carpal tunnel. Its long axis being from above downward, laterally, and forward. The medial surface has two facets, a flattened semi-lunar facet articulating with the lunate bone, and an inferior concave facet, articulating alongside the lunate with the head of the capitate bone. The palmar surface is concave forms a tubercle and gives attachment to transverse carpal ligament. The dorsal surface of the bone is narrow having a groove which runs along the length of the bone giving attachment to ligaments. The anatomical inferior surface which is smooth, convex, triangular is divided into two parts by a slight ridge [10].

The scaphoid bone gains its blood supply by dorsal and palmar branches of radial artery, supplying middle and distal parts neglecting the proximal part, which relies upon retrograde blood flow. The most commonly injured carpal bone is scaphoid as it is amidst of the carpal rows, so, high attention prevents the delayed union and post operative osteoarthritis. Non-unions can result in loss of blood supply to the proximal pole, which can result in avascular necrosis of the proximal segment [2,3].

Study of morphometric features of scaphoid is useful during reconstruction of scaphoid and to assess the length of the screw for internal fixation for scaphoid fractures [5]. Knowledge of vascular foramina helps in evaluating the vascularity of different segments of the bone and explaining the risk of avascular necrosis. As there is paucity of literature we concluded our work with limited parameters and references.

Material and Methods

The study included one hundred dry human scaphoid bones (50 left and 50 right) which were obtained from the Department of anatomy, Narayana medical college, Nellore, India. The bones were of unknown age, sex, race, and religion. The bones with underlying pathology were excluded. The morphometric parameters were measured with vernier caliper of 0.02 mm accuracy; the circumference was measured by placing a thread around them and measuring its length. A magnifying lens was used to observe the number of foramina.

Morphological Parameters

The scaphoid tubercle was assessed based on its shape (either conical or pyramidal) (Fig. 1). The presence of tubercle, waist, dorsal sulcus, ridge for

the origin of scapho capitate ligament (SCIL) and the sulcus for flexor carpi radialis (FCR) were noted (Fig. 2). Dorsal sulcus was assessed by its presence, shape and number (primary or secondary sulci). The foramina in the main sulcus and secondary sulcus were noted. The foramina in the proximal and distal regions were counted as well. The shapes of the scapholunate joint surface were recorded as half moon or crescent (Fig. 3) [7].

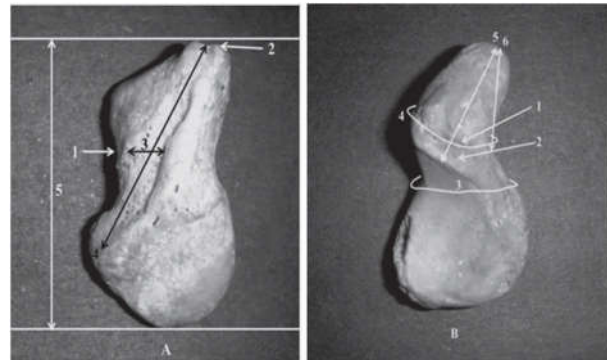


Fig. 1: Morphological and morphometric parameters

A. 1. Scaphoid waist 2. Tubercle 3. Width of dorsal sulcus 4. Length of Dorsal Sulcus 5. Length of scaphoid.

B. 1. Ridge for scl 2. Sulcus for flexor carpi radialis 3. Waist circumference 4. Tubercle circumference 5. Primary height of tubercle 6. Secondary height of tubercle

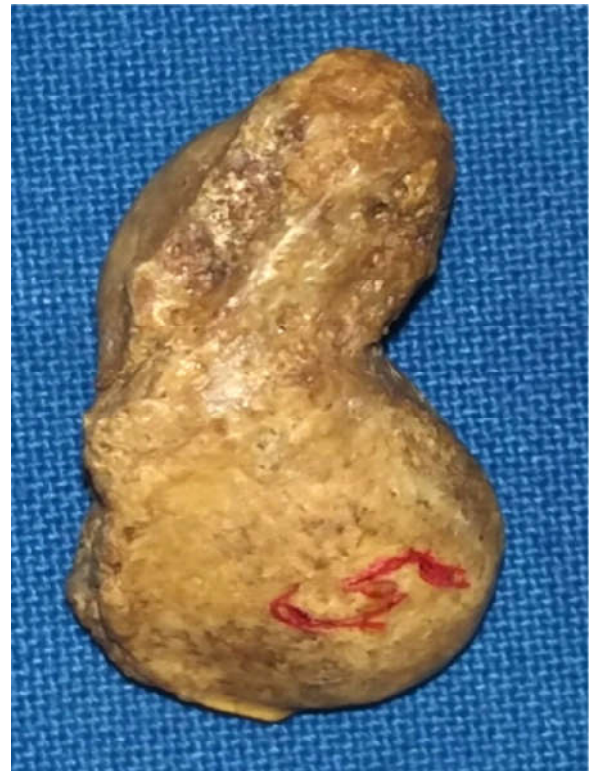

Fig. 2(a): double sulcus

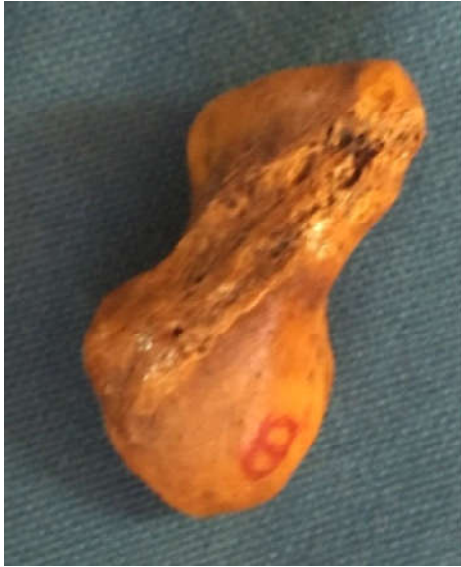

Fig. 2(b): y shaped sulcus

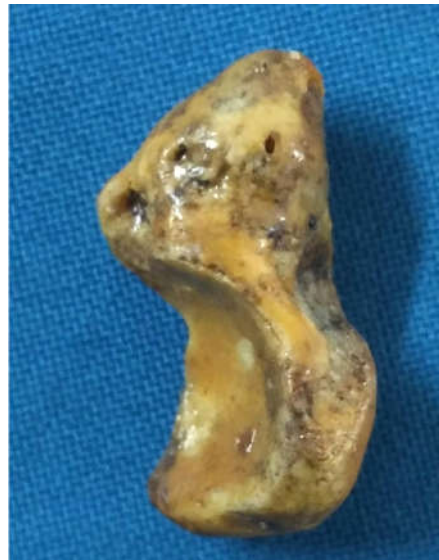

Fig. 4: Number of nutrient foramina

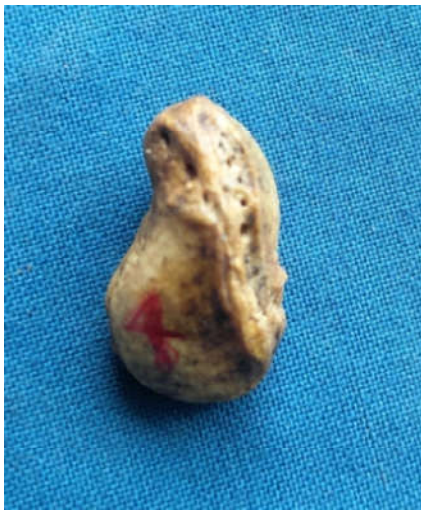

Fig. 2(c): Y shaped sulcus

Fig. 2: Shape of the tubercle and presence of single sulcus

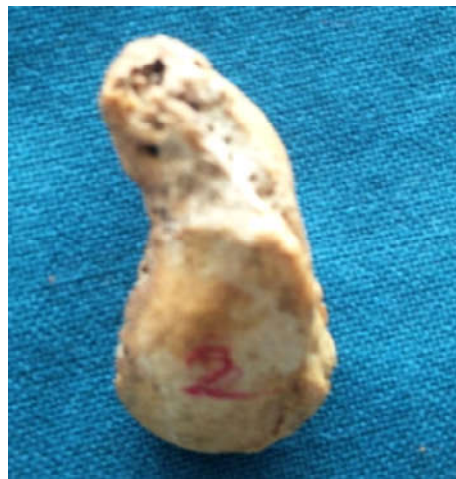

Fig. 5: Four nutrient foramina in left scaphoid

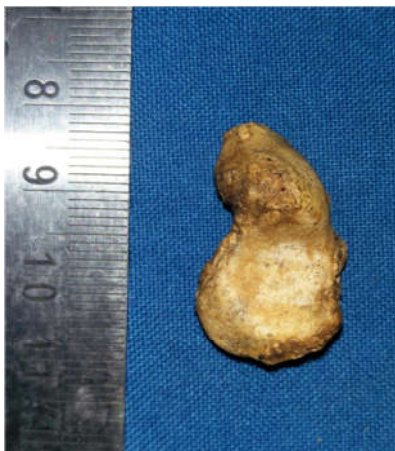

Fig. 3: Shape of scapholunate joint surface

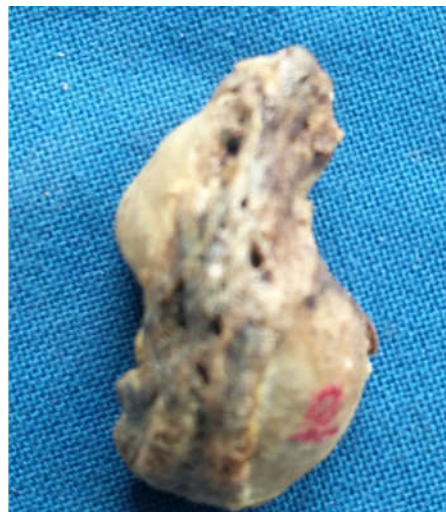

Fig. 6: Six nutrient foramina in right scaphoid

Morphometric Parameters

The length of the scaphoid was calculated by distance between the most prominent points of proximal articular surface and the tubercle (Fig. 2). The width of scaphoid was measured at three different regions (proximal, waist and distal). The proximal width was defined as the maximum width towards the proximal articular surface of the bone. Width of the waist was calculated at the narrowest angle of the waist. The distal width was calculated at the widest part of the distal part of the bone. The length and width of the dorsal sulci were also measured. The circumference of the waist were measured at its narrowest point, circumference of the tubercle were measured at its base. The primary and secondary heights of the tubercle were measured. Primary height of the tubercle was defined as the distance between the most prominent point of tubercle and the intersection of the anterior and superior ridges of the scapholunate articular surface. The secondary height of the tubercle was defined as the most prominent point of the tubercle and the deepest point of the waist. The statistical analysis of the morphometric parameters was performed and each variable was investigated and correlated individually with reference to the side [7].

Observations and Results

The morphological features of the bone are presence of tubercle in all the 100 bones out of which 50 belong to right and 50 belong to left side. Waist was observed in 99 bone out of which 50 are left and 49 right side. Dorsal sulcus was seen 97 bones out of which 48 right and 49 left. Ridge for origin of SCIL 81 out of which 40 are right sided and 41 left sided. Sulcus for FCR was seen in 80 bones and 42 belong to right side and 38 to left side. Their parameters are mentioned in (Table 3). The mean length of the scaphoid of left side was 26.2 mm and of right side was 26.4 mm with a standard deviation of 2.406 and 2.067 respectively (Grpahs 1 & 2). The tubercle was present in all the scaphoid bones. Among the left scaphoid bones, 22 were of conical shape and 28 were pyramidal shape (Table 1). Similarly 36 right scaphoid tubercles were of conical shape and 14 were of pyramidal shape. The waist was absent in 1 scaphoid of right side, rest of all the bones had waist. The dorsal sulcus was absent in 1 scaphoid of left side and 2 on the right side (Table 1) The shape of scapholunate articular surface was noted as either half moon or crescentic shape (Table 5). Among them, 38 scaphoids of left side had the shape of half moon and 12 were of

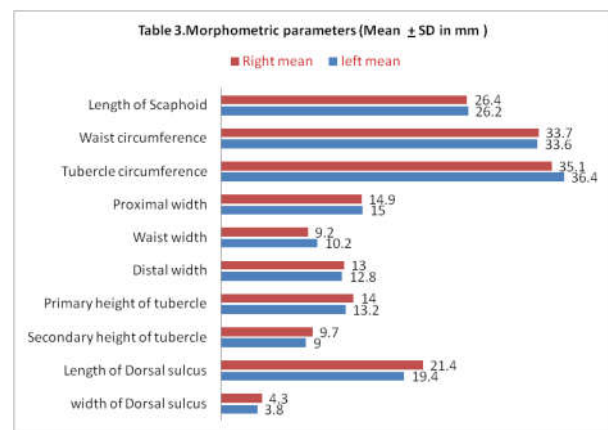
crescentic. Similarly 36 of right side were of half moon and 14 were of crescentic. The shape and variations of the dorsal sulcus were noted. Most of the scaphoid had main (single) dorsal sulcus 63%. In contrast, 29% had two dorsal Sulci and 6% had a Y shaped sulcus. Foramina in the dorsal sulcus were counted, all the scaphoids had a minimum of one foramen in the main dorsal sulcus and 92% had more than one foramen (Table. 4). All scaphoids which presented with secondary sulci had a foramen in it. The ridges for the origin of scapholunate interosseous ligament were present in 41 scaphoids of left side and 40 of right side. Sulci of flexor carpi radialis were also seen and it was present in 38 scaphoids of left side and 42 of right side.

Table 1: Showing the frequency of shape of the tubercle

Shape	LEFT (n=50)	RIGHT (n=50)
Conical	22	36
Pyramidal	28	14
Total	50	50

Table 2. Presence of morphological features

Features	Left (n=50)	Right (n=50)	Total (n=100)
Tubercle	50	50	100
Waist	50	49	99
Dorsal Sulcus	49	48	97
Ridge for Origin of Scil	41	40	81
Sulcus Of Fcr	38	42	80




Graph 1:

Table 3: Showing the frequency of the shape of dorsal sulcus

Dorsal sulcus	Left (n=50)	Right (n=50)
Single sulcus	40	23
Double sulcus	9	19
Y shaped sulcus	0	6
Total	49	48

Table 4: Showing the presence of average number of foramina

Left	Right
3.8%	4.9%

**Graph 2:****Table 5:** Showing the frequency of the shape of the Scapho lunate joint

SHAPE	Left (n=50)	Right(n=50)
Half Moon	20	28
Crescent	30	22
Total	50	50

Discussion

Morphometric Parameters

In the present study, the mean length of the scaphoid of left side was 26.2 mm and of right side was 26.4 mm with a standard deviation of 2.406 and 2.067 respectively. Muralidhar [9] studied the mean length of the scaphoid to be mm on the 24.97 mm on the right side and 23.86 mm on the left side. In a study in North-Eastern population, Purushothama [7] reported the mean length of scaphoid as 22.33 mm and 22.65 mm on the right and left sides. Our morphometric parameters in the present study are higher than those findings of the comparative authors. We can assess the screw length for pre operative internal fixation by accurate knowledge of the mean length. Similarly the waist circumference was statistically significant and relatively more than left thus explaining greater force transmission on dominant side according to Wolfe's law (It is developed from German Anatomist and Surgeon Julius Wolfe (1836-1902) states that bone in healthy person will adopt to the loads under which it is placed).

Numbers of vascular foramina are noted on volar and dorsal surface. A total of 190 (3.8%) Nutrient Foramen are seen in 50 left side scaphoid and 244 (4.9%) nutrient foramen are seen in 50 right side scaphoid. This may be due to right side dominance. Foramina in the dorsal sulcus were counted, all the scaphoids had a minimum of one foramen in the main dorsal sulcus and 92% had more than one foramen (Fig. 5). Owira et al., [8] classified scaphoids into type I (no foramina), type II (1-2 foramina) and type III (more than 2 foramina). Owira [8] observed type I (no foramina) scaphoids in 54% cases. It can be stated that in such cases when there is a fracture of waist, there will be diminished blood supply to the proximal fragment leading to nonunion or avascular necrosis. In 26.92% bones there is one foramen and in 67.3% bones more than one foramen is observed in the study by Muralidhar [9]. Similar findings were stated by Dubey et al. [6], who reported the same in 17.72% and 82.28% bones respectively

The present study observed that tubercles were present in all scaphoids and the height and circumference of base of the tubercle were strongly correlating with each other Number of vascular foramina is more on the dorsal surface (1-24) than volar surface (3-7). This finding is consistent with Dubey et al., Owira et al., and Muralidhar [6,7,8] who reported that dorsal to volar ratio is 4:1, 4.23:1 and 3.42:1 respectively. In the present study also it is 3.42:1.

Conclusion

The scaphoid fracture occurs in young healthy individuals and is the most commonly fractured bone of the wrist (50%-80% of all carpal bone injury) and avascular necrosis is the most common clinical event. The complex shape of scaphoid and its orientation within the carpus makes the radiological interpretation of scaphoid anatomy difficult. The goals of reconstructive surgery for scaphoid fracture non unions include restoration of normal scaphoid length and shape by use of the contraletal scaphoid bone as a geometric model. Apt knowledge of scaphoid anatomy is useful to radiologists, orthopedicians, anthropologists, forensic medicine and clinical anatomist.

References

1. Easley, Robert W. Beasley's Surgery of the Hand. New York: Thieme. 2003. ISBN 978-1-282-95002-3. OCLC 657589090.

2. Eathorne, Scott W. The wrist: clinical anatomy and physical examination—an update. *Primary care*. 2005 Mar;32(1):17-33. doi:10.1016/j.pop.2004.11.009. PMID 15831311.
3. Gray, Henry (1918). 6b. The Hand. 1. The Carpus. *Anatomy of the Human Body*. Bartleby.com.
4. Drake, Richard L.; Vogl, Wayne; Mitchell, Adam W.M. *Gray's anatomy for students*. Illustrated by Richard Tibbitts and Paul Richardson. Philadelphia: Elsevier/Churchill Livingstone. 2005. ISBN 978-0-8089-2306-0. OCLC 646533128.
5. Anderson, Kenneth; Anderson, Lois E.; Glanze, Walter D. *Mosby's Medical, Nursing & Allied Health Dictionary* (4th ed.). St. Louis: Mosby. 1994.p.1396. ISBN 978-0-8016-7225-5. OCLC 461378724.
6. Dubey PP, Navneet Kumar Chauhan, Siddiqui MS. Vascular foramina of scaphoid and its clinical implications. *Biomedical Research*. 2011;22(2):201-4.
7. Purushothama C, sarada RK, Konuri A, Tamang BK, Gupta C, Murlimanju. Morphological and morphometric features of scaphoid bone in north eastern population, India. *Nepal Med Coll J*. 2011;13(1):20- 23
8. Owira P, Kigera J, Saidi H. Distribution of scaphoid nutrient foramina. *The Annals of African Surgery*. 2016;13(2):49-51.
9. Muralidhar Reddy Sangam. Study of Morphometry of Scaphoid and Its Vascular Foramina. *Int J Anat Res*. 2017;5(4.2):4563-65.
10. Inderbir singh's. *Textbook of Anatomy*, vol.1, 6th edition, pp.114.
11. AK Datta. *Essential of Human Anatomy*, superior and inferior extremities, vol.3. p.20.

.....

Study of Variation in the Position of Greater Palatine Foramen in North Karnataka Population

Ratna Prabha J¹, Uday Kumar²

Abstract

68 non- pathological dried adult crania were studied measurement between greater palatine foramen and incisive fossa of both right and left side were measured and compared prevalence of greater palatine foramen (GPF) in relation to molar teeth on either side was studied. Direction of GPF was also studied. All the measurement was taken by vernier calipers. The comparative study measurement of GPF with incisive fossa on both sides- mean value of right GPF was 37.4 (SD \pm 1.22) and mean value of left was 37.2 (SD \pm 1.24) and $p < 0.5$. the p value was insignificant. The prevalence of GPF in relation to molar teeth on both sides Right side 3 (4.41%) opposite to 2nd molar 20 (29.4%) between 2nd and 3rd molar 36 (52.9%) opposite to 3rd molar 9 (13.2%) Behind 3rd molar. On left side 2 (2.94%) opposite to 2nd molar 11 (16%) between 2nd and 3rd molars 48 (70.5%) opposite to 3rd molar 7 (10.2%) Behind 3rd molar. The direction of position of GPF was on right side 22 (32.3%) forward position, 12 (17.6%) forward lateral position, 34 (50%) forward and medial position on left side, 21 (30.8%) forward position 10 (14.7%) forward and lateral position, 37 (54.4%) forward and middle position. This anatomical approach to GPF will helpful to Dentists, Maxillo facial surgeons and plastic surgeons moreover Anaesthetists too, because morphometric values of mesodermal derivatives' are uncertain.

Keywords: Greater Palatine Foramen=Gpf; Dentist; Maxillo Facial and Plastic Surgery; Vernier Calipers.

How to cite this article:

Ratna Prabha J & Uday Kumar. Study of Variation in the Position of Greater Palatine Foramen in North Karnataka Population. Indian J Anat. 2019;8(2):107-109.

Introduction

Greater palatine foramen which is the lower orifice of greater palatine canal opens, close to the lateral border of the palate immediately behind the palate maxillary suture. This greater palatine foramen is otherwise called as posterior palatine foramen. The foramen transmits greater palatine nerve and vessels. The palatine artery is a branch from third part of maxillary artery arises in pterygopalatine

fossa, descend in the greater palatine canal emerges through greater palatine foramen to alveolar border of the hard palate it ascends and anastomose with a branch of sphenopalatine artery [1].

It is an important anatomic landmark for Dentists, Maxillofacial surgeons and plastic surgeons. The foramen is also crucial for being the point entrance of the palatine canal for reaching the pterygo palatine ganglion [2]. The block of greater palatine nerve by anesthesia which innervates the posterior part of hard palate in the greater palatine foramen is largely used in the minor oral surgeries, periodontics and general dentistry. Moreover the area of the greater palatine foramen (GPF) serves as donor of soft tissue graft [3]. Hard palate grafting is a successful and commonly practised approach in oculoplasty surgeries for eyelid and socket reconstruction. Vascularization of the mucoperiosteum of hard palate comes mainly from greater palatine vessels [4,5]. Hence position, prevalence and distance from molar teeth of GPF

Author's Affiliation: ¹Assistant Professor ²Associate Professor, Department of Anatomy Navodaya Medical College, Mantralayam Road, Navodaya Nagar, Raichur, Karnataka 584103, India.

Corresponding Author: Uday Kumar, Associate Professor, Department of Anatomy Navodaya Medical College, Mantralayam Road, Navodaya Nagar, Raichur, Karnataka 584103, India.

E-mail: vastushilpi@gmail.com

Received 26.02.2019 | **Accepted** 26.03.2019

is must to approach. Hence attempt was made to study the same in the crania of North Karnataka

Material and Methods

Sixty eight non –pathological dried adult crania were selected for study. Among 68 crania 5 female crania were also studied but due to similar features of greater palatine foramen they were merged with remaining male crania.

Following measurements were taken by digital vernier caliper

- a. Distance between greater palatine foramen and incisive fossa of both right and left were measured and compared
- b. Prevalence greater palatine foramen in relation to molar teeth on both (right and left) side were studied with percentage
- c. Direction of greater palatine foramen on either side were studied with percentage

Pathological and broken crania were excluded from the study. The duration of study was about three years (February 2015 to December 2018)

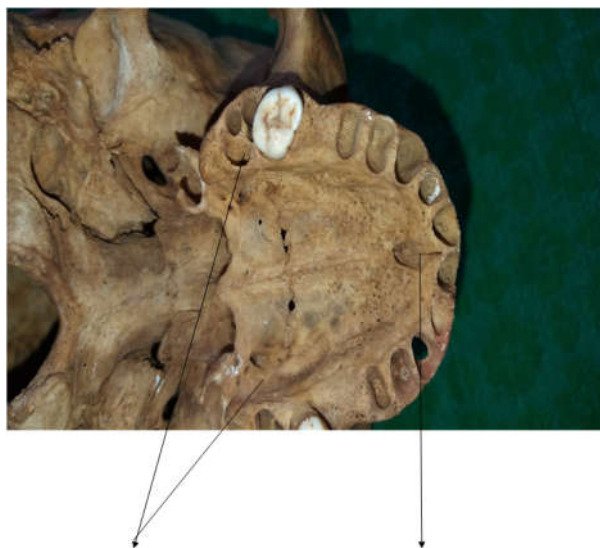


Fig. 1: Greater Palatine foramen. Incisive Fossa

Observation and Results

Table 1- Comparative study of measurement of distance of Greater palatine foramen to Incisive fossa on both sides mean value of right Greater palatine foramen was 37.4 (SD± 1.22) and mean value of left greater palatine foramen was 37.2 (SD ± 1.24) and p<0.5 and p value is insignificant.

Table 2- Prevalence of greater palatine foramen in relation to molar teeth

- a. Opposite to second molar tooth right side 3 (4.4%) and left side 2 (2.94%) and total number were 5 (3.67%)
- b. Between 2nd and 3rd molars right side 20 (29.4%) left side 11 (16.31%) and total 31 (22.7%)
- c. Opposite to 3rd molar teeth - right side 36 (52.9%) and left 48 (70.5%) and total 84 (61.7%)
- d. Behind 3rd molar teeth - right side 9 (13.2%) and left 7 (10.2%) and total 16 (11.7%)

Table 3- Direction of position of greater palatine foramen.

- a. Forward position - right side 22 (32.3%) and left 21 (30.8%) and total 43 (31.6%)
- b. Forward and lateral position - right side 12 (17.6%) and left 10 (14.7%) and total 22 (16.1%)
- c. Forward and medial position - right side 34 (50%) and left 37 (54.4%) and total 71 (52.2%)

Table 1: Comparative study of measurements of distance Greater palatine foramento Incisive fossa on both sides (No of Crania 68)

Right Greater Palatine Foramen		Left Greater Palatine Foramen		P Value	Result
Mean	SD	Mean	SD		
37.4	±1.22	37.2	±1.24	P< 0.5	In significant

p value is Insignificant

Table 2: Prevalence Greater palatine foramen in relation to molar teeth (No of Crania 68)

Particular	Right side		Left side		Total	
	No	%	No	%	NO	%
Opposite to 2 nd & 3 rd Molars	3	4.41	2	2.94	5	3.67
Opposite to 3 rd molar	36	52.9	48	70.5	84	61.7
Behind 3 rd molar	9	13.2	7	10.2	16	11.7

Table 3: Direction of position Greater palatine foramen

Particular	Right side		Left side		Total	
	No.	%	No.	%	No.	%
Forward position	22	32.3	21	30.8	43	31.6
Lateral position	12	17.6	10	14.7	22	16.1
Forward & medial position	34	50	37	54.4	71	52.2

Discussion

In the present study of variation in the position of GPF in North Karnataka population. The comparative study of measurement of distance between GPF and Incisive fossa on right side mean value was 37.4 (SD± 1.22) and left side mean value was 37.2 (SD± 1.24) the p value was (p<0.5) insignificant (Table 1). The prevalence of GPF in relation to molar teeth on either side on right side 3 (4.4%) opposite to 2nd molar 20 (29.4%) between 2nd and 3rd molar, 36 (52.9%) opposite to 3rd molar 9 (13.2%) behind 3rd molar on left side, 2 (2.94%) opposite to 2nd molar, 11 (16.1%) between 2nd and 3rd molar, 48 (70.5%) opposite to 3rd molar 7 (10.2%) behind 3rd molar (Table 2). The direction of position of GPF was on right side 22 (32.3%) forward position, 12 (17.6%) forward and lateral position, 34 (50%) forward and medial position on left side 21 (30.8%) forward position, 10 (14.7%) forward & lateral position 37 (54.4%) forward and medial position (Table 3). These findings were more or less in agreements with previous studies [5,6,7].

These variations in the position of GPF could be attributed to different degrees of sutural growth at palato maxillary suture and appositional growth of posterior border of maxilla. There is also change in the position of GPF with age. As eruption of molar teeth occurs. The position of GPF moves posteriorly [8]. Moreover as an evolutionary point of view the foramen of cranial base move laterally in the man because there is great reduction in the size of muscles of mastication, the bizygomatic and bitympanic breath are also reduced across the modern human crania [9].

In addition to this rate of bone growth and maturation is influenced not only by age and sex but economic status individual body weight, racial difference also to be taken into account [10]. Bone is a essentially living tissue supplied with blood vessels and nerves, not only external form but also its internal architecture can change in response to the stress and strains to which it is subjected during life.

Summary and Conclusion

The present cranial study of variations in the position of GPF in North Karnataka population will be quite useful for Dentists, Maxillo- facial surgeons,

plastic surgeons for surgical approach. But this study demands further genetic, embryological, nutritional, anthropological and environmental study because the factors which determine the mechanism and time of ossification of cranial base are still obscure.

This research work was approved by ethical committee Navodaya Medical College Mantralayam road Navodaya Nagar Raichur (Karnataka 584103).

No conflict of Interest

No funding

References

1. Stranding .S- infrottemporal and ptrygo palatine and temporo mandibular joint study Grays Anatomy. The anatomical basis of clinical practice 4th edition London Elsevier, Churchill living stone 2005,545-546.
2. Ikuta CR, Cardoso C L- Position of greater palatine foramen an anatomical study through cone beam computed tomography images, AM J of Anthropology. 2010;27(2)88-92.
3. Swati Tiwari, Shilpa Agarwal, Neelam Vasudev Topography of greater palatine foramen in North Indian population - key to successful maxillary nerve block. Global J of Res Analysis. 2017;6(12):2277-8160.
4. Sushobhana, Suniti Raj, Mishra, Shailaindra Singh Anatomical study and clinical consideration of greater palatine foramen in adult human skulls of north Indian population. Int. J of Anatomy Radiology and surgery. 2015 Oct;4(4):41-46.
5. Howlans J.M Isln D. Maxillary nerve block the pterygo palatine canal, a modified techniques and case report Aust. dent. J. 1998;26:658-64.
6. Mastudo Y. Location of dental foramen in human skulls from statistical observation. Int.J.orthod oral surg radiol. 1927;18:299-300.
7. Wong J D Sved AM. Maxillary block Anesthesia via greater palatine canal a modified techniques and case reports. Aust.Dent.J. 1991;31:15-21.
8. Slavkin HC, Confer MR. An anatomic study of pterygo maxillary region in the cranium of infants and children oral surgery. 1966;21:225-35.
9. Weidenreich F. The skulls of sinanthropus pekineiss, comparative study on primitive hominid skull palaeontologiasinica, New services DN 10. Geological surgery of China. 1943.pp.89-98.
10. Weiner J S and Thambipillai V. Skeletal maturation of west African Negroes. Am J. Phys Anthropol. 1952;10:32-38.

REDKART.NET

(A product of RF Library Services (P) Limited)

(Publications available for purchase: Journals, Books, Articles and Single issues)

(Date range: 1967 to till date)

The Red Kart is an e-commerce and is a product of RF Library Services (P) Ltd. It covers a broad range of journals, Books, Articles, Single issues (print & Online-PDF) in English and Hindi languages. All these publications are in stock for immediate shipping and online access in case of online.

Benefits of shopping online are better than conventional way of buying.

1. Convenience.
2. Better prices.
3. More variety.
4. Fewer expenses.
5. No crowds.
6. Less compulsive shopping.
7. Buying old or unused items at lower prices.
8. Discreet purchases are easier.

URL: www.redkart.net

A Study on Foramen Magnum Morphometry in 3-Dimensional CT Scans and Dry Skulls and its Neurosurgical and Forensic Implications

Venkatesh G Kamath¹, Md Tabrej Alam²

Abstract

Background: A study on foramen magnum morphometry has immense neurosurgical and forensic implications due to its association with myriad intracranial tumours and sexual dimorphism. **Aims and Objectives:** To study dimensions of foramen magnum in 3-dimensional CT Scans and dry skulls. **Methodology:** Sagittal and transverse dimensions of the foramen were measured in 50 three-dimensional CT scans and 100 dry skulls. The data obtained was statistically analysed using Student's t-test for significance, binary logistic regression and ROC curve for sexual dimorphism. **Results:** The mean sagittal dimension was 32.01 ± 3.92 mm in dry skulls and 33.26 ± 3.86 mm in CT Scans. The transverse dimension was 27.68 ± 2.32 mm in dry skulls and 28.31 ± 2.08 mm in CT scans. In dry skulls mean foraminal area in males was $698.46 \text{ mm}^2 \pm 105.32 \text{ mm}^2$ and in females it was $590.87 \text{ mm}^2 \pm 98.45 \text{ mm}^2$. In CT scans it was $705.23 \text{ mm}^2 \pm 111.22 \text{ mm}^2$ in males and $602.16 \text{ mm}^2 \pm 76.23 \text{ mm}^2$ in females. The dimensions were significantly more in males than in females and sagittal dimension was observed to have a sex predictability of 67.8%, transverse dimension 62.6% and area 69.7%. **Conclusion:** The foramen magnum exhibits sexual dimorphism and is a marker for forensic sexing. A knowledge of shape and dimensions of foramen magnum has diverse neurosurgical implications owing to its proximity to hypoglossal canal, medulla oblongata, pons, spinal cord, cerebellum and related intracranial tumours.

Keywords: Binary Logistic Regression; CT Scan, Foramen Magnum; Forensic sexing; Neurosurgery.

How to cite this article:

Venkatesh G Kamath & Md Tabrej Alam. A Study on Foramen Magnum Morphometry in 3-Dimensional CT Scans and Dry Skulls and its Neurosurgical and Forensic Implications. Indian J Anat. 2019;8(2):111-115.

Introduction

Foramen magnum has immense neurosurgical implications owing to its proximity to vital neuroanatomical structures such as the medulla oblongata, spinal cord and hypoglossal nerve [1]. It also exhibits variations in shape which are clinically significant [2]. The foramen is also associated with

achondroplasia and Arnold-Chiari malformations and knowing the foramen dimensions helps understanding pathophysiology of such conditions [3,4]. The transcondylar approach is the most favoured approach preferred by neurosurgeons operating on intracranial tumours in the region of the brainstem [5]. Stenosis of the foramen results in increased intracranial tension which in turn results in compression of brainstem, cranial nerves and hindbrain causing clonus, lower cranial nerve palsy, respiratory complications and cardiac manifestations like hypotension [6]. The foramen also exhibits sexual dimorphism and is a useful tool for forensic sexing [7]. Foramen magnum morphology is often unaltered in cases of burns and explosions owing to its concealed location [8]. It was observed that 24 out of 25 cranial dimensions studied exhibited sexual dimorphism and hence foramen magnum is used along with these dimensions to conclusively determine sex during

Author's Affiliation: ¹Associate Professor, Department of Anatomy, G.S.L. Medical College, NH-16, Laxmipuram, Rajanagaram, East-Godawari district, Rajanagaram, Andhra Pradesh 533296, India. ²Assistant Professor, Department of Anatomy, Hind Institute of Medical Sciences, Mau, Ataria, Sitapur, Uttar Pradesh 261303, India.

Corresponding Author: Md Tabrej Alam, Assistant Professor, Department of Anatomy, Hind Institute of Medical Sciences, Mau, Ataria, Sitapur, Uttar Pradesh 261303, India.

E-mail: drtabrezmd@gmail.com

Received 17.02.2019 | **Accepted** 06.03.2019

forensic analysis [9]. The dimensions of foramen magnum are studied in dry skulls in diverse ethnic groups [10,11]. However, there are few studies in CT Scans [12,13] and in this study the dimensions in dry skulls are compared with CT-Scans. A study on the shape and dimensions of the foramen has immense implications both in neurosurgery and forensic analysis.

Materials and Methods

The study was conducted using skulls from South Indian ethnic group and North Indian ethnic group in two medical institutes. The study involved 100 dry skulls (65 male and 35 female) and fifty three-dimensional CT Scans (30 male and 20 female). Only those skulls which were well ossified without any deformities in the foramen were included in the study. Those with deformed and fractured foramen were excluded. Only adult well ossified skulls were used during the study. Only those CT Scans where the foramen was clearly visualised were included. Sliding digital calliper (Lianying 0005) graduated to the last 0.01mm was used for all measurements.

The dimensions of the foramen were measured in dry skulls as shown in figure 1. The dimensions were measured in three dimensional CT Scans as shown in figure 2. The midsagittal plane meets anterior border of the foramen at a point called basion and the posterior border at a point called opisthion. The basion was marked as point A and opisthion as point B and distance AB was marked as the anteroposterior diameter of the foramen. Two most lateral points of the foramen C and D were marked. The distance CD was noted as the transverse diameter of the foramen. The measurements were repeated twice for accuracy and a third measurement was taken if there was a difference of more than 0.1mm. The foramen area was calculated by Radinsky's formula.

$$\text{Foramen magnum Area} = \frac{1}{4} \times \pi \times t \times s$$

The data obtained was analysed using SPSS computer software and Student's t-test for statistical significance. Binary logistic regression analysis and receiver operating characteristic curve were used for determining the sex predictability of the dimension.

Results

The mean anteroposterior diameter was 32.01 ± 3.92 mm in dry skulls and 33.26 ± 3.86 mm in CT Scans. The transverse dimension was 27.68 ± 2.32 mm in dry skulls and 28.31 ± 2.08 mm in CT scans. On statistical analysis using Student's t-test no significant difference was observed in dimensions between dry skulls and CT Scans.

In dry skulls, the mean anteroposterior diameter was 34.32 ± 1.02 mm in males and 30.26 ± 1.23 mm in females. The mean transverse dimension was 28.13 ± 2.05 mm in males and 24.86 ± 1.64 mm in females. On statistical analysis using Student's t-test significant difference was observed in dimensions ($p < 0.001$) between males and females in dry skulls.

In CT Scans, the mean anteroposterior diameter was 35.68 ± 1.23 mm in males and 31.03 ± 1.52 mm in females. The mean transverse dimension was 29.14 ± 1.13 mm in males and 25.21 ± 1.89 mm in females. On statistical analysis using Student's t-test significant difference was observed in dimensions ($p < 0.001$) between males and females in CT Scans.

In dry skulls, the mean foraminal area in males was $698.46 \text{ mm}^2 \pm 105.32 \text{ mm}^2$ and in females it was $590.87 \text{ mm}^2 \pm 98.45 \text{ mm}^2$. On statistical analysis, it was observed that in males the area of the foramen was significantly larger ($p < 0.001$) than in females in dry skulls.

In CT scans, the mean foraminal area in males was $705.23 \text{ mm}^2 \pm 111.22 \text{ mm}^2$ and in females it was $602.16 \text{ mm}^2 \pm 76.23 \text{ mm}^2$. On statistical analysis, it was observed that in males the area of the foramen was significantly larger ($p < 0.001$) than in females in CT Scans.

Binary logistic regression analysis and receiver operating characteristic curve revealed that the anteroposterior dimension has sex predictability of 67.8%, transverse dimension a sex predictability of 62.6% and area a sex predictability of 69.7%. The descriptive statistics of anteroposterior dimension, transverse dimension and area of the foramen in males and females both in dry skulls and CT Scans is shown in Table 1.

Table 1: Depicts the descriptive statistics of anteroposterior dimension, transverse dimension and area of the foramen in males and females both in dry skulls and CT Scans.

Dimension in millimetre	Dry Skulls Mean \pm SD		CT Scans Mean \pm SD	
	Males	Females	Males	Females
Sagittal	34.32 ± 1.02	30.26 ± 1.23	35.68 ± 1.23	31.03 ± 1.52
Transverse	28.13 ± 2.05	24.86 ± 1.64	29.14 ± 1.13	25.21 ± 1.89
Area	698.46 ± 105.32	590.87 ± 98.45	705.23 ± 111.22	602.16 ± 76.23

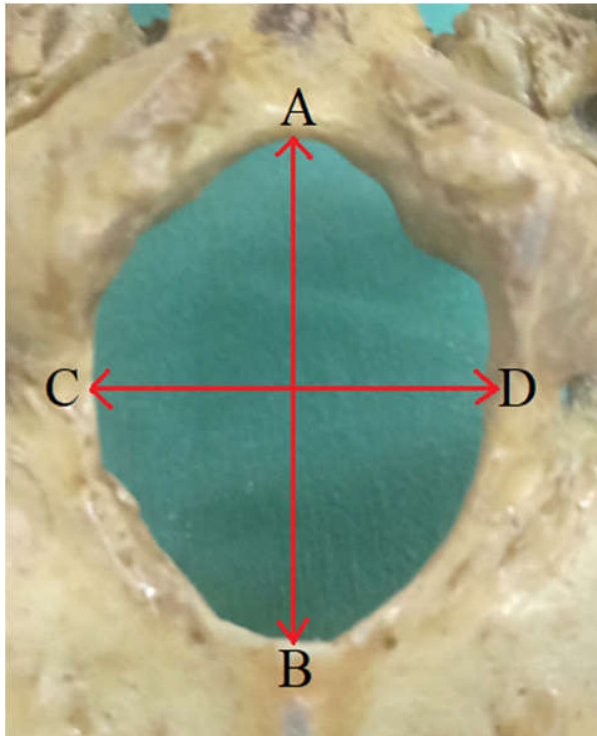


Fig. 1: depicts measurement of dimensions of the foramen in dry skulls.
AB: Anteroposterior diameter, CD: Transverse diameter

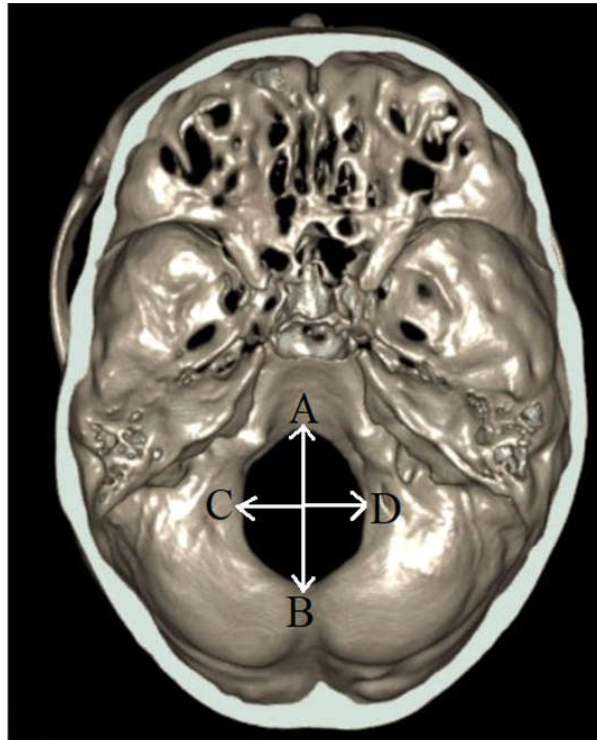


Fig. 2: depicts measurement of dimensions of the foramen in 3-dimensional CT Scans.
AB: Anteroposterior diameter, CD: Transverse diameter

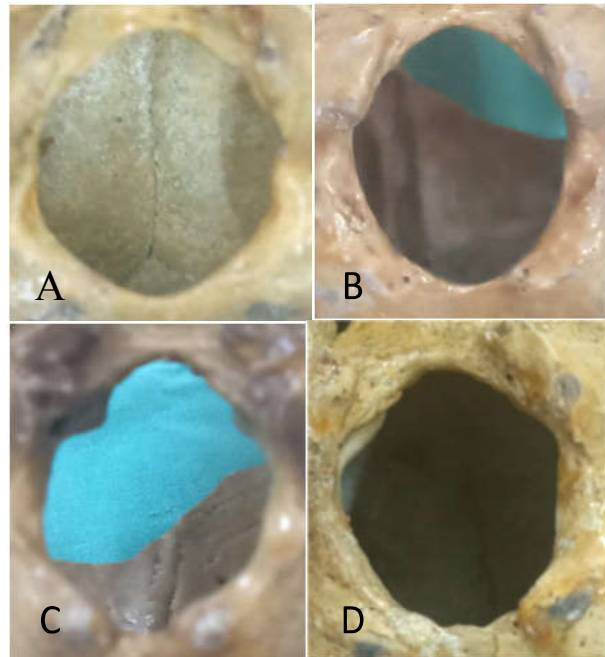


Fig. 3: depicts the different shapes of foramen magnum
A: Rounded, B: Oval, C: Irregular, D: Polygonal

The anteroposterior diameter was consistently more than the transverse diameter and this observation is consistent with the shape of foramen magnum. The anteroposterior diameter was observed to range from a maximum value of 38.32 mm to a minimum value of 27.84 mm. The transverse diameter ranged from a maximum value of 31.54 mm to a minimum value of 21.21mm. In the anteroposterior diameter the value repeated the greatest number of times was 33.54 mm and in transverse diameter it was 25.54 mm.

The shape of the foramen was also studied and the foramen was classified based on shape into round, oval, irregular and polygonal. The different shapes are shown in figure 3. It was observed that 33.2% of the foramen were oval, 30.4% polygonal, 20.3% rounded and 16.1% irregular. The foramen shows diverse variations in shape and these variations are clinically significant for neurosurgeons.

Discussion

It is essential to understand the shape and dimensions of foramen magnum as any narrowing of the foramen can result in compression of vital structures like the brain stem resulting in damage to respiratory and cardiac centres and damage to lower cranial nerves [6]. The foramen is closely related to the hypoglossal canal and also plays an important role in the pathophysiology of Arnold

Chiari Malformations [4]. The transcondylar approach allows the neurosurgeon to access pathologies such as tumours ventral to brainstem and cervicomedullary region [5].

The shape of the foramen shows significant variation, the most common shape being oval and foramen with greater anteroposterior diameter permit more access to structures during neurosurgical procedures [2]. There are four primary cartilaginous centres surrounding the foramen during development and these unite to form the foramen [14]. The different shapes of the foramen can be attributed to the manner in which these centres unite [15]. The foramen also develops very early during embryogenesis and within 5-7 years of age it is completely fused [16].

In our study it was observed that the most common shape was oval (33.2%), followed by polygonal (30.4%), rounded (20.3%) and irregular (16.1%) varieties. Similar findings were observed by Garcia et al. (45% oval) [17] and Zaidi and Dayal (64% oval) [18]. Chetan et al. observed that the frequency of oval variety was 15.1%, egg-shaped 18.9%, tetragonal 18.9%, hexagonal 5.6% and pentagonal 3.8% [19]. Murshed et al. observed that the frequency of oval variety was 8.1% and the egg-shaped variety was 6.3% [2]. A review into these studies establishes the fact that the shape of the foramen is observer biased. Moreover, the foramen shape depends on manner in which the primary cartilaginous centres around the foramen unite during development.

In the present study, the mean anteroposterior diameter was 32.01 ± 3.92 mm in dry skulls and 33.26 ± 3.86 mm in CT Scans. The anteroposterior diameter reported by other studies include 31 ± 2.4 mm by Chethan et al. [19], 31mm by Tubbs et al. [20], 35.9 ± 3.3 mm by Murshed et al. [2] and 36 ± 2 mm by Wanebo and Chicoine [21].

In the present study, the transverse dimension was 27.68 ± 2.32 mm in dry skulls and 28.31 ± 2.08 mm in CT scans. The transverse diameter reported by other studies include 25.2 ± 2.4 mm by Chethan et al. [19], 27mm by Tubbs et al. [20], 30.4 ± 2.6 mm by Murshed et al. [2] and 32 ± 2 mm by Wanebo and Chicoine [21].

In our study, in dry skulls the mean foraminal area in males was $698.46 \text{ mm}^2 \pm 105.32 \text{ mm}^2$ and in females it was $590.87 \text{ mm}^2 \pm 98.45 \text{ mm}^2$. In CT scans, the mean foraminal area in males was $705.23 \text{ mm}^2 \pm 111.22 \text{ mm}^2$ and in females it was $602.16 \text{ mm}^2 \pm 76.23 \text{ mm}^2$. In a similar study by Vinutha et al. in CT Scans the mean foraminal area in males was 799.29

$\pm 134.05 \text{ mm}^2$ and in females it was $697.77 \pm 116.63 \text{ mm}^2$ [22].

The foramen dimensions and area exhibit sexual dimorphism and can be used along with other cranial sexually dimorphic parameters to conclusively determine the sex. In our study anteroposterior dimension, transverse dimension and area showed significant sexual dimorphism ($p < 0.001$). Similar observations were made by Vinutha et al. in their study involving foramen in CT Scans [22].

The foramen magnum dimensions are studied in diverse ethnic groups and it is observed that they exhibit ethnic variation. The dimensions are studied in dry skulls and CT Scans and several authors are of the opinion that there is no significant difference in values between skulls and radiographs [23]. Variations in dimensions and shape have diverse clinical implications for neurosurgeons operating in the vicinity of the foramen and in understanding the pathophysiology of Arnold Chiari Malformation [12].

Conclusion

A study on the shape and dimensions of foramen magnum has diverse clinical and forensic implications. The proximity of the foramen to the brainstem, hypoglossal canal, lower four cranial nerves and the contents of posterior cranial fossa increases its clinical significance and it plays a significant role in the pathogenesis of diseases in this region. This includes Arnold Chiari Malformation Type 1, Tonsillar herniation, compression of medulla in stenosis of the foramen and several other regional pathologies. The transcondylar approach is frequently used by neurosurgeons operating on intracranial tumours in the region of the brainstem. The foramen dimensions also exhibit sexual dimorphism and the sagittal and transverse dimensions are more in males than females. The foramen dimensions along with other sexually dimorphic cranial parameters can be used in forensic analysis to conclusively determine sex. The most commonly observed foramen shape was oval in this study. Neurosurgeons operating in the vicinity of the foramen must be aware of variations in its shape and dimensions.

References

1. Standring S. Editor. Gray's Anatomy: The Anatomical Basis of Clinical Practice. 40th ed.

- Philadelphia: Elsevier Churchill Livingstone; 2008. p.424.
2. Murshed KA, Cicekcibasi AE, Tuncer I. Morphometric evaluation of the foramen magnum and variations in its shape: A study on computerized tomographic images of normal adults. *Turk J Med Sci.* 2003;33:301-06.
 3. Hecht JT, Horton WA, Reid CS, Pyeritz RE, Chakraborty R. Growth of the foramen magnum in achondroplasia. *Am J Med Genet.* 1989;32:528-35.
 4. Aydin S, Hanimoglu H, Tanriverdi T, Yentur E, Kaynar MY. Chiari type I malformations in adults: A morphometric analysis of the posterior cranial fossa. *Surg Neurol.* 2005;64:237-41.
 5. Muthukumar N, Swaminathan R, Venkatesh G, Bhanumathy SP. A morphometric analysis of the foramen magnum region as it relates to the transcondylar approach. *Acta Neurochir (Wien).* 2005;147:889-895.
 6. Kanodia G, Parihar V, Yadav YR, Bhatele PR, Sharma D "Morphometric analysis of posterior fossa and foramen magnum. *J Neurosci Rural Pract.* 2012;3:261-6.
 7. Y. G'unay and M. Altink'Ok. The value of the size of foramen magnum in sex determination. *Journal of Clinical Forensic Medicine.* 2000;7:147-49.
 8. T.D. Holland. Use of the cranial base in the identification of fire victims. *Journal of Forensic Sciences.* 1989;34:458-460.
 9. Mahakkanukrauh P, Sinthubua A, Prasitwatanaseree S, Ruengdit S, Singsuwan P, Praneatpolgrang S, Duangto P. Craniometric study for sex determination in a Thai population. *Anat Cell Biol.* 2015;48:275-83.
 10. U. Ukoha, O.A. Egwu, I.J. Okafor, A.E. Anyabolu, G.U. Ndukwe, I. Okpala. Sexual dimorphism in the Foramen Magnum of Nigerian adult. *International Journal of Biological and Medical Research.* 2011; 2:878-881.
 11. F. Burdan, J. Szumito, J. Walocha et al. Morphology of the foramen magnum in young Eastern European adults. *Folia Morphologica.* 2012;71:205-216.
 12. Iqbal S, Robert AP, Mathew D. Computed tomographic study of posterior cranial fossa, foramen magnum, and its surgical implications in Chiari malformations. *Asian J Neurosurg.* 2017; 12:428-35.
 13. F. H. Erdil, V. Sabanciogullari, M. Cimen, and O. Isik. Morphometric analysis of the foramen magnum by computed tomography. *Erciyes Medical Journal.* 2010;32:167-170.
 14. L. A. Madeline and A. D. Elster. Suture closure in the human chondrocranium: CT assessment. *Radiology.* 1995;196:747-56.
 15. F. Govsa, M.A. Ozer, S. Celik, N.M. Ozmutaf. Three dimensional anatomic landmarks of the foramen magnum for the craniovertebral junction. *The Journal of Craniofacial Surgery.* 2011;22:1073-1076.
 16. R. Gapert, S. Black, J. Last. Sex determination from the foramen magnum: discriminant function analysis in an eighteenth and nineteenth century British sample. *International Journal of Legal Medicine.* 2009;123:25-33.
 17. E.E.Garcia, A.P.Carlos, O.B. Leandro, C.L. Erika, S.M. Hector. Tomographic Morphometry of the foramen magnum and its relation to sex and Mapuche ethnicity. *Academic Journals Database* 2011;5:28-31.
 18. Zaidi SH, Dayal SS. Variations in the shape of foramen magnum in Indian skulls. *Anat Anz Jena* 1988;167:338-340.
 19. P. Chethan, K.G. Prakash, B.V. Murlimanju et al. Morphological analysis and morphometry of the foramen Magnum: An anatomical investigation. *Turkish Neurosurgery.* 2012;22:416-19.
 20. Tubbs RS, Griessenauer CJ, Loukas M, Shoja MM, Cohen Gadol AA. Morphometric analysis of the foramen magnum: An anatomic study. *Neurosurgery.* 2010;66:385-388.
 21. Wanebo JE, Chicoine MR. Quantitative analysis of the transcondylar approach to the foramen magnum. *Neurosurgery.* 2001;49:934-941.
 22. Vinutha SP, Suresh V, Shubha R. "Discriminant Function Analysis of Foramen Magnum Variables in South Indian Population: A Study of Computerised Tomographic Images. *Anat Res Int* 2018; Article ID 2056291, 8 pages.
 23. Vidya C.S., Madhu B. Foramen Magnum - Dry bone study and review of studies from India. *NJCA* 2018;7:5-11.
-

Indian Journal of Anatomy

Library Recommendation Form

If you would like to recommend this journal to your library, simply complete the form below and return it to us. Please type or print the information clearly. We will forward a sample copy to your library, along with this recommendation card.

Please send a sample copy to:

Name of Librarian

Name of Library

Address of Library

Recommended by:

Your Name/ Title

Department

Address

Dear Librarian,

I would like to recommend that your library subscribe to the Indian Journal of Anatomy. I believe the major future uses of the journal for your library would provide:

1. useful information for members of my specialty.
2. an excellent research aid.
3. an invaluable student resource.

I have a personal subscription and understand and appreciate the value an institutional subscription would mean to our staff.

Should the journal you're reading right now be a part of your University or institution's library? To have a free sample sent to your librarian, simply fill out and mail this today!

Stock Manager

Red Flower Publication Pvt. Ltd.

48/41-42, DSIDC, Pocket-II

Mayur Vihar Phase-I

Delhi - 110 091(India)

Phone: Phone: 91-11-45796900, 22754205, 22756995, Cell: +91-9821671871

E-mail: sales@rfppl.co.in

Correlative Study of Length and Breadth of Mastoid Process with Cranial Index in North Karnataka Crania

Ratna Prabha J¹, Uday Kumar²

Abstract

Forty eight (48) male and 28 female, non - pathological, dried adult crania were studied. The cranial Index (CI) length and breadth of mastoid process (MP) on both sides were also measured. C.I was measured by winged caliper and MP was measured by vernier calipers. Male CI was 68.6 (SD±0.46) mean length of right MP was 2.66 (SD ± 0.18) mean left Breadth of MP 0.81 (SD ± 0.4). The CI of Female was 72.5, (SD ± 1.19) and mean length of MP right side in female crania was 2.60 (SD ± 0.23) mean length MP (left) side was 2.20 (SD ± 0.16) mean breadth of MP in female (right side) was 0.86 (SD ± 0.05) mean breadth of MP in female (left side) was 0.81 (SD ± 0.04). Correlation coefficient of CI in male and length of MP (right side) was 0.75 t test was 7.09 and p Value was highly significant (p<0.01) and length of MP (left side) was 0.74, t test was 7.46 and p value was highly significant (p<0.01) correlative coefficient of CI with Breadth of Mp (right side) was - 0.83 cm t test value was 10.0 and p value was highly significant (p<0.01) and Breadth of MP (left) side was - 0.72cm t test value was 7.03 p value was highly significant (p<0.01). The correlation coefficient of CI of Female crania study CI with length of MP (right side) mm 0.87 t test value was 8.9 p value was highly significant (p<0.01) CI with length of MP (left side) was 0.83 t test value was 7.5 P value was highly significant (p<0.01) CI with Breadth of MP (right side) was - 0.81 t test value was 7.04 p value was highly significant (p<0.01). CI with Breadth of Mp (left side) was - 0.82 t test value was 7.3 p value was highly significant (p<0.01). In the comparison study of male and female cranial parameters In males mean value of CI was 68.6 (SD ± 0.46) and mean value CI of female was 72.5 (SD ± 1.19) and the t test value was - 20.1 and the p value was highly significant (p<0.01) mean value of male MP length (right side) was 2.66 (SD ± 0.10) and mean value in female MP right side was 2.60 (SD ± 0.23) t test value was 1.64. P value was highly significant (p<0.01) mean value of length of MP (left side) in male crania was 2.11cm (SD ± 0.15). Mean value in female MP (left side) was 2.20 (SD ± 0.16) t test value was -2.60 p value was highly significant (p<0.01) mean value of breadth of MP (right side) in male crania was 0.82 (SD ± 0.05) and mean value in female MP (right side) 0.86 (SD ± 0.05) t test value was - 3.15 and p value was highly significant (p<0.01). Mean value of breadth of male crania (left side) was 0.81 (SD ± 0.04) and in female crania breadth of MP was 0.81 (SD ± 0.04) t test value was 0.79 and p value was insignificant (p>0.05) This correlative coefficient study is quite useful for ENTsurgeons, Radiologists, Medico - legal experts, Anthropologist and Anatomists because By knowing the value of one parameter like C.I one can explore the both sides MP and vice versa.

Keywords: CI Cranial Index Mp= Mastoid Process; Winged Calipers; Vernier Calipers.

How to cite this article:

Ratna Prabha J & Uday Kumar. Correlative Study of Length and Breadth of Mastoid Process with Cranial Index in North Karnataka Crania. Indian J Anat. 2019;8(2):117-121.

Introduction

Mastoid process is a prominent breast like inferior projection from the mastoid part of temporal bone and is located postero-inferiorly to the external acoustic meatus. It has two surfaces i.e lateral and medial surface [1]. Lateral surface has muscular attachments viz sterno mastoid, splenius capitis, longissimus capitis and medial surface is grooved deeply called mastoid notch from where posterior belly of digastric arises, and occipital groove observed medial to mastoid notch in this groove

Author's Affiliation: ¹Assistant Professor ²Associate professor, Department of Anatomy, Navodaya Medical College, Mantralayam Road, Navodaya Nagar, Raichur, Karnataka 584103, India.

Corresponding Author: Uday Kumar, Associate professor, Department of Anatomy, Navodaya Medical College, Mantralayam Road, Navodaya Nagar, Raichur, Karnataka 584103, India.

E-mail: vastushilpi@gmail.com

Received 26.02.2019 | **Accepted** 26.03.2019

lodges occipital artery [2]. The mastoid process is not present at birth, it may owe its existence to the pull of the muscles inserted into, and is usually better developed in men than women mastoid processes (MP) projects downwards and forwards immediately behind the meatus [3]. More over MP are found only in the gorilla and man being well developed in the latter and rudimentary in former. The free poise of the human head up on the spinal column as a recession of jaws, the back ward growth of brain and the erect standing posture are no doubt responsible for development of MP and for the greater mobility of the head in rotating movements [4].

As the MP also projects into internal ear consists of mastoid antrum, gets infected along with ear hence surgical approach to ear is through MP only. Hence normal length and breadth of MP has to be differentiated from pathological MP. By knowing the CI of the patient ENT surgeon or Radiologist can explore the normal length and breadth of MP, Moreover in Medico-legal practice by studying broken crania of any side with intact MP medico-legal expert can explore the whole crania. Apart from this these values express regional or anthropological and anatomical significance. Hence attempt was made to correlate C.I with MP in both sexes crania which appears to be a quite new method.

Material and Method

Forty eight (48) male and 28 female non pathological dried adult crania were studied. The crania were put in anatomical position cranial length was measured from Nasion to Inion. Cranial breadth was measured from one supra mastoid crest to another. These measurements were taken by winged caliper. The length and breadth of mastoid process on both sides was measured by vernier calipers.

$$\text{Cranial Index} = \frac{\text{cranial breadth} \times 1001}{\text{Cranial length}}$$

Table 1: Average values of Male crania

	Cranial index	Length (Right)	Length (Left)	Breadth (Right)	Breadth (Left)
Mean	68.60	2.66	2.11	0.82	0.81
SD	0.46	0.10	0.15	0.05	0.04

Table 2: Average values of female crania

	Cranial index	Length (Right)	Length (Left)	Breadth (Right)	Breadth (Left)
Mean	72.54	2.60	2.20	0.86	0.81
SD	1.19	0.23	0.16	0.05	0.04

The pathological and broken crania were excluded from the study

The duration of study was about three years.

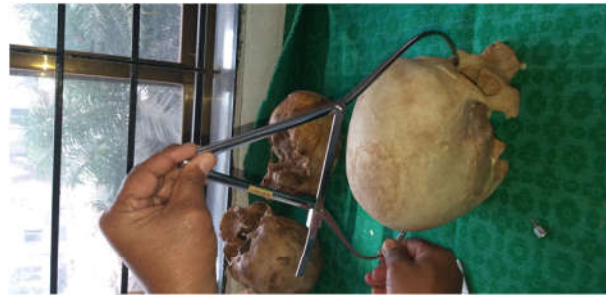

Fig. 1:

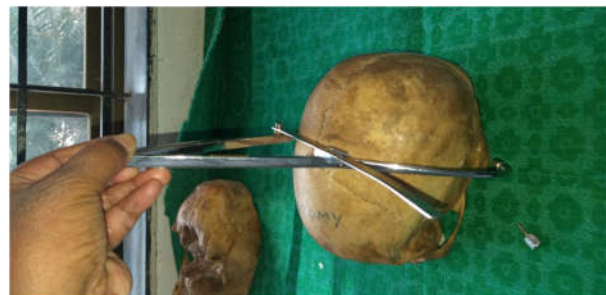

Fig. 2:

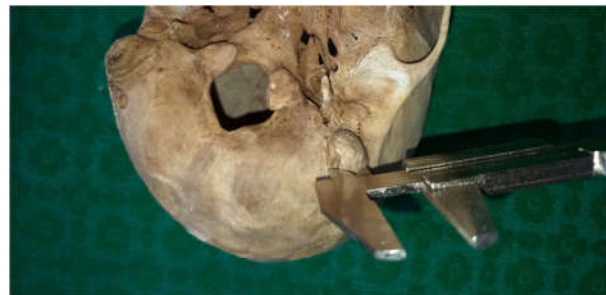

Fig. 3:

Observation and Results

Table-1 Average values of male crania- mean value of cranial Index (CI) was 68.6 (SD \pm 46) mean value of length of right mastoid process was 2.6 (SD \pm 0.10) left mastoid process length was 2.07 (SD \pm 0.12). The breadth of mastoid process on right side was 0.82 (SD \pm 0.05) left side 0.81 (SD \pm 0.04).

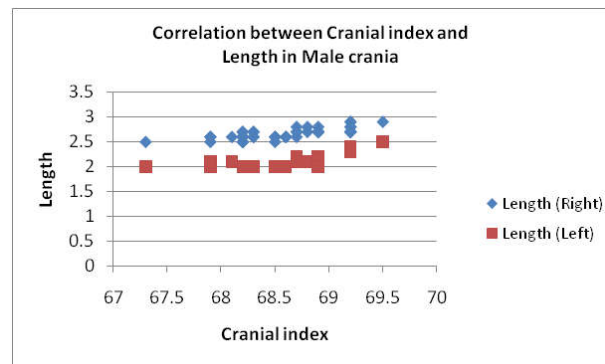
Table-2 Average values of female crania- value CI was (SD ± 1.19) length of mastoid process on right side was 2.60 (SD ± 0.23) on left side it was 2.19 (SD ± 0.17) Breadth of the mastoid process on right side was 0.86 (SD + 0.05) on left side it was 0.80 (SD±0.04)

Table-3 correlation of CI with length and breadth of Male crania

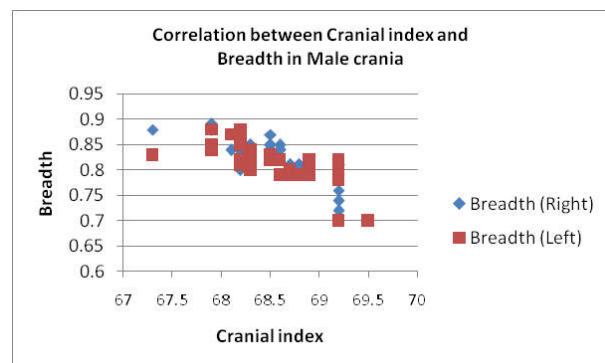
- a. Correlation coefficient CI with right mastoid process (MP) length was 0.75, t test 7.69 p value was highly significant (p<0.01)
- b. Correlation coefficient of CI with Length of MP (left side) was 0.74 t test was 7.46 p value was highly significant (p<0.01)
- c. Correlative coefficient of CI with Breadth of MP (Right side) was 0.83, t test was 10.0 p value was highly significant. (p<0.01)
- d. Correlative coefficient of CI with Breadth of MP (left side) was - 0.72 t test was 7.03 p value was highly significant (p<0.01)

Table 3: Correlation of Cranial index with Length and Breadth in Male crania

Cranial index	Length (Right)	Length (Left)	Breadth (Right)	Breadth (Left)
Correlation coefficient	0.75	0.74	-0.83	-0.72
t test	7.69	7.46	10.09	7.03
p value	p<0.01	p<0.01	p<0.01	p<0.01



Graph 1:



Graph 2:

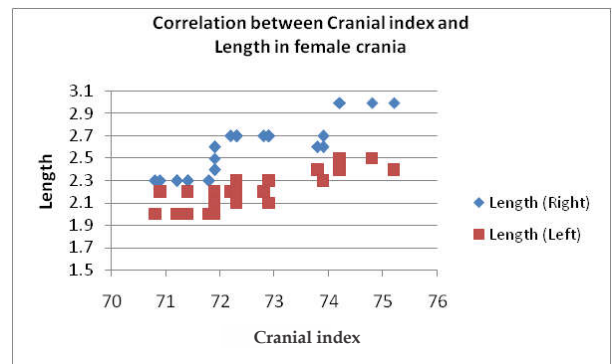
Statistically highly significant positive correlation observed between Cranial index and Length (p<0.01) while highly significant negative correlation observed between Cranial index and Breadth (p<0.01) in male

Table-4 correlation of CI with length and Breadth of MP in Females crania

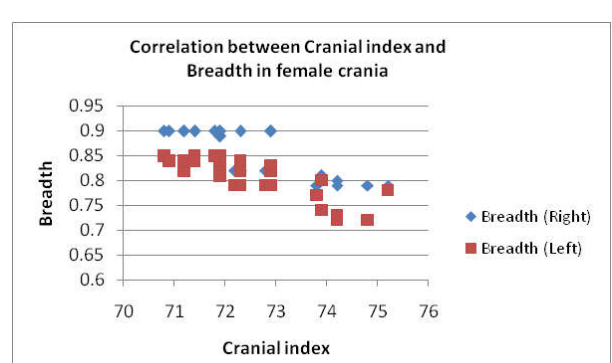
- a. Correlative coefficient of CI with length of MP (right) was 0.87 t test was 8.99 P value was highly significant (p<0.01)
- b. Correlative coefficient of CI with length of MP (left) was 0.83 t test was 7.58 P value was highly significant (p< 0.01)
- c. Correlative coefficient of CI with Breadth of MP (Right) was -0.81 t test was 7.04, P value was highly significant (p<0.01)
- d. Correlative coefficient of CI with MP Breadth (left) was - 0.82, t test was 7.30 p value highly significant (p<0.01)

Table 4: Correlation of Cranial index with Length and Breadth in Female crania

Cranial index	Length (Right)	Length (Left)	Breadth (Right)	Breadth (Left)
Correlation coefficient	0.87	0.83	-0.81	-0.82
t test	8.99	7.58	7.04	7.30
p value	p<0.01	p<0.01	p<0.01	p<0.01



Graph 3:



Graph 4:

Statistically highly significant positive correlation observed between Cranial index and Length ($p < 0.01$) while highly significant negative correlation observed between Cranial index and Breadth ($p < 0.01$) in female.

Table 5 comparison of male and female parameters of CI and MP

- CI of Male was 68.6 (SD \pm 0.40) and CI of Female was 72.5 (SD \pm 1.19) t test was - 20.1 and p value was highly significant ($p < 0.01$)
- Mean value length of Male Mp right side was 2.66 (SD \pm 0.10) and Female right side MP was 2.60 (SD \pm 0.23) t test was 0.23 p value was significant ($p < 0.05$)
- Mean value length of Male MP (left side) was 2.11 (SD \pm 0.15) and Female MP (left side) was 2.20 (SD \pm 0.16) t test was 2.60 p value was highly significant ($p < 0.01$).
- Mean Breadth of MP (right side) in Male was 0.82 (SD \pm 0.05) and in Females 0.86 (SD \pm 0.05) t test was 3.15 p value was highly significant ($p < 0.01$).
- Mean value of male MP Breadth (left side) was 0.81 (SD \pm 0.04) and in female 0.81 (SD \pm 0.4) t test value was 0.79 p value was insignificant ($p < 0.05$).

crania. The mean value of CI in Male crania was 68.6 (SD \pm 0.46) mean length of MP (right side) was 2.66 cm (SD \pm 0.10) and MP (left side) was 2.11 (SD \pm 0.15) mean Breadth of MP (right side) was 0.82 (SD \pm 0.05) and left MP was 0.81 (SD \pm 0.04) (Table 1).

The mean values of parameters in Female crania was CI was 72.5 (SD \pm 1.10) mean length of MP (MP) (right side) was 2.60 (SD \pm 0.23) and MP (left) was 2.20 (SD \pm 0.16) mean value of breadth of MP (right) was 0.86 (SD \pm 0.06) and breadth of MP (left) was 0.81 (SD \pm 0.04) (Table 2).

a. The correlation of CI with length and breadth of MP in male crania was correlative coefficient of CI with length of MP (right) was 0.75 t test value was 7.69 and p value was highly significant ($p < 0.01$) length of (b) correlative coefficient of CI with length of MP (left) was 0.74, t test value was 7.46 p value was highly significant ($p < 0.01$) (c) correlative coefficient of breadth of MP (right) was 0.83, t test value was 10.09 and p value was highly significant ($p < 0.01$) (d) correlative coefficient of CI with breadth of MP (left) was -0.72, t test value was 7.03, and p value was highly significant ($p < 0.01$) (Table 3). Correlation of CI with length and breadth of MP in female crania was - (a) correlative coefficient of CI with length of MP (right) was 0.87, t test value was 8.99 p value

Table 5: Comparison of male and female parameters

		Cranial index	Length (Right)	Length (Left)	Breadth (Right)	Breadth (Left)
Male	Mean	68.60	2.66	2.11	0.82	0.81
	SD	0.46	0.10	0.15	0.05	0.04
Female	Mean	72.54	2.60	2.20	0.86	0.81
	SD	1.19	0.23	0.16	0.05	0.04
	t test	-20.15	1.64	-2.60	-3.15	0.79
	p value	$p < 0.01^{**}$	$p < 0.05^*$	$p < 0.01^{**}$	$p < 0.01^{**}$	$p > 0.05$

*Significant, **highly significant

Statistically significant difference observed in right Length of male and female ($p < 0.05$) and highly significant difference observed in Cranial index, left Length of male and female ($p < 0.01$).

While highly significant difference observed in right breadth of male and female ($p < 0.01$).

But no significant difference observed in left breadth of male and female ($p > 0.05$)

Discussion

In the present study of correlative study of length and breadth of MP with CI, in the North Karnataka

was highly significant ($p < 0.01$) (b) Correlative coefficient of CI with length of MP (left) was 0.83 t test was 7.58 and p value was highly significant ($p < 0.01$) (c) correlative coefficient of CI with breadth of MP (right) was - 0.81 t test was 7.04 p value was highly significant ($p < 0.01$) (d) correlative coefficient of CI with Breadth of MP (left) was - 0.82 t test was 7.30 p value was highly significant (Table 4).

Comparison of parameters of male and female crania was (a) Mean value of CI in male 68.6 (SD \pm 0.46) and female CI was 72.5 (SD \pm 1.19) t test value was -20.15 p value was highly significant ($p < 0.01$) (b) mean value of length of MP (right) in Male crania was 2.66 cm (SD \pm 0.10) and Female 2.60 (SD \pm 0.23)

t test value was 1.64 p value was significant ($p < 0.05$) (c) Mean value of length of MP (left) in Male crania was 2.11 (SD ± 0.16) t test value was -2.60 and p value was highly significant ($p < 0.05$) (d) mean value of breadth of Male (right) was 0.82 (SD ± 0.05) and in Female 0.86 (SD ± 0.05) t test value was -3.15 P value was highly significant ($p < 0.01$) (e) Mean value of breadth of Male (left) was 0.81 cm (SD ± 0.04) and Female was 0.81 (SD ± 0.04) and t test was 0.79 p value was in significant ($p > 0.05$) (Table 5). These different values were more or less in agreement with previous studies [5,6,7].

The length and breadth variations in both sexes and on both sides could be due to developmental factor. The otic capsules develop number of calcification centers that unite to become a petrosal bone. The petrosal first located in the lateral wall of neurocranium

Due to expansion of cerebral hemisphere it was relegated to the ventro lateral position called mastoid process [8]. Moreover evolution insofar affects various parts of the body has been asymmetrical. The lower extremities attained their man-like form before the skull, similarly the skull and its various parts also exhibits evidences of asymmetric evolution which results into variations of length and breadth of MP [9].

As petromastoid bone had various ossification centres. These centers may express their morphological individuality which may results into variations into length and breadth of MP. It is also reported that tubercle, tuberosties, processes (or projections) are formed in direct response to the pull of tendons or ligaments [10]. It is presumed that probable function of MP was related to degree of development and pull of several muscles attached to it and presumably related to balance of the head on the spinal column against gravity.

Summary and conclusion

The present study of correlative study of length and breadth MP with CI of north Karnataka population would be useful to ENT surgeons, Radiologists, Medico-legal experts, Anthropologists and Anatomists to explore the normal length and breadth of MP by studying the CI of the patients

or person before or after the Ear (mastoidectomy) surgeries to preserve the facial nerve and occipital artery. Anthropologist can differentiate present CI and MP with other region of India and abroad But this study further demands genetic, bio-mechanical, anthropological, embryological and nutritional study because exact mechanism and formation of mastoid process is still unclear.

This research paper was approved by ethical committee of Navodaya Medical College, mantralayam road, Navodaya Nagar, Raichur 584103 Karnataka

No conflict of Interest

No funding

References

1. Grays Anatomy, the anatomical basis of clinical practice 40th edition Susanslandering Elsevier Churchill living stone London. 2008,22.
2. Nafis Ahmed Farooqui - Clinical oriented Human Anatomy 1st edition Universal Book House 3-A-o Market - Jail Road Aligarh publication. 1999;320-21.
3. Ernest Frazer J. Anatomy of human skeleton - 3rd edition J and A Churchill 40, Gloucester place Portman square, 1933.pp.221-22.
4. Gros clark W.E. The tissues of the body 6th edition oxford at the clarendon press 1972.pp.111-14.
5. Hoshi H. Sex difference in the shape of mastoid process in norma occipitalis and importance to the sex determination of Human skull. Okajimasfolia. AnatJapanica. 1962;38:309-17.
6. Paiva IAS, segre M. Sexing the human skull through the mastoid process. Rev. Hosp Cl n Fac Med Sao Paulo. 2003;58(1):15-20.
7. Gupta AD, Banarjee A. Discriminant function analysis of mastoid measurements in sex determination. J life SC. 2012;4(1).
8. Gorge Kent - comparative Anatomy of vertebrates 2nd edition The C.V Mosby Co. publisher Tokyo Japan. 1969.pp.181-82.
9. Hooton EA- up from ape 1st edition (revised)the Mac millan company new York. 1963.pp.88-89.
10. Henry cushier Raven 3rd edition New York Columbia university press. 1950.pp.227-51.

.....

STATEMENT ABOUT OWNERSHIP AND OTHER PARTICULARS**“Indian Journal of Anatomy” (See Rule 8)**

1. Place of Publication : Delhi
2. Periodicity of Publication : Quarterly
3. Printer's Name : **Asharfi Lal**
Nationality : Indian
Address : 3/258-259, Trilok Puri, Delhi-91
4. Publisher's Name : **Asharfi Lal**
Nationality : Indian
Address : 3/258-259, Trilok Puri, Delhi-91
5. Editor's Name : **Asharfi Lal** (Editor-in-Chief)
Nationality : Indian
Address : 3/258-259, Trilok Puri, Delhi-91
6. Name & Address of Individuals : **Asharfi Lal**
who own the newspaper and particulars of : 3/258-259, Trilok Puri, Delhi-91
shareholders holding more than one per cent
of the total capital

I Asharfi Lal, hereby declare that the particulars given above are true to the best of my knowledge and belief.

Sd/-
(Asharfi Lal)

Abnormal Origin of the Right Coronary Artery: A Case Report with Literature Review

Dhanesh Kumar Sharma¹, Meryl Rachel John², Nikita Chaudhary³

Abstract

Anomalous origin of right coronary artery is a rare congenital anomaly that was 1st described in 1948 by White and Edwards. It is well established that an anomalous origin of right coronary artery may be asymptomatic but it can lead to angina pectoris, myocardial infarction and sudden death, even in the absence of atherosclerosis. So, although many of these anomalies are clinically insignificant but some are associated with serious morbidity. Incidence of coronary anomalies in patients undergoing coronary angiography varies from 0.64% to 1.3%. We described the case of corresponding author, who had history of breathlessness off and on in the early morning in lying down posture relieved on seating posture; and once a moderate pain along the medial aspect of his right arm and then the evaluation revealed an anomalous right coronary artery arising at a higher level. We discussed the clinical importance of this anomaly and reviewed the literature concerning current views and therapy. Conceptual and therapeutic debates remain. Aim of present study is to reappraise the concept of anomalous origin of coronary artery and to discuss the potential hazards and treatment rationale of this anomaly on the basis of literature review. A comprehensive literature review was made.

Keywords: Coronary Arteries; Anomalies; Angiography Catheterization; Morbidity.

How to cite this article:

Dhanesh Kumar Sharma, Meryl Rachel John, Nikita Chaudhary. Abnormal Origin of the Right Coronary Artery: A Case Report with Literature Review. Indian J Anat. 2019;8(2):123-126.

Case Report

One day in the morning in December 2018, the corresponding author at his present age of 62 developed a moderate pain in the morning along the medial aspect of his right arm. He had history of breathlessness off and on in the early morning in lying down posture which relieved on seating posture since his age of 24. On investigation he was having systolic murmur over aortic area and prominent T wave in Electrocardiography. Trade

mill test and echocardiography were without any significant finding. For last 3 years he was under antihypertensive drug medication. And then this once moderate pain along the medial side of his right arm on evaluation in angiography revealed an abnormal right coronary artery arising at a higher level in ascending aorta. Otherwise he was an energetic individual with full of life and had not previously had any problem with chest pain or breathlessness on exertion. The episode of moderate pain lasted for about 12 hours with intervals of disappearance of pain for a few seconds or minutes. During episode, there was no any occurrence or association of palpitations or chest pain etc.

Angiography revealed nonocclusive coronary artery disease with anomalous high derivation of right coronary artery above the level of right aortic sinus. A minor plaque in the distal part of left anterior descending branch of left coronary artery and also a minor plaque in the distal part of left circumflex branch of left coronary artery were found. (Figs. 1 and 2)

Author's Affiliation: ¹Additional Professor and Head ²PG Junior Resident ³PG Junior Resident, Department of Anatomy, All India Institute of Medical Sciences, Raipur, Chhattisgarh 942099, India.

Corresponding Author: Dhanesh Kumar Sharma, Additional Professor and Head, Department of Anatomy, All India Institute of Medical Sciences, Raipur, Chhattisgarh 942099, India.

E-mail: dhyanesh.sharma@gmail.com

Received 13.03.2019 | **Accepted** 16.04.2019

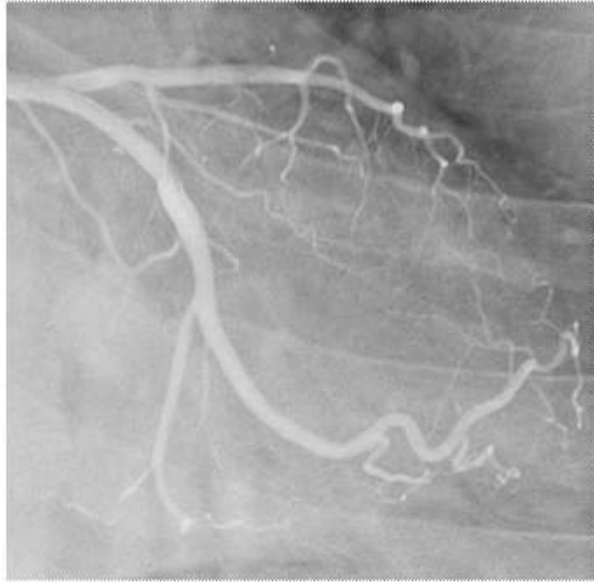

Fig. 1: LCA

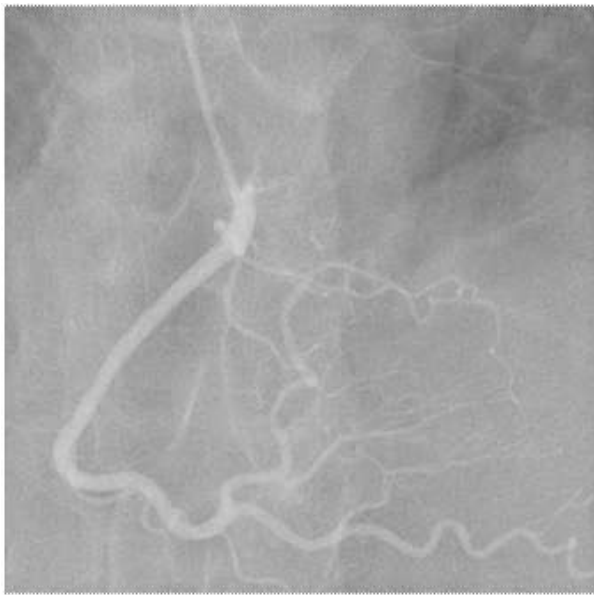

Fig. 2: RCA

Discussion

The coronary arteries transport blood into and out of the cardiac muscle of the heart and they comprise the left and right coronary arteries with their branches. The coronary arteries are also distinguished as the epicardial lying above the epicardium and the microvascular lying close to the endocardium) [1]. The right coronary artery (RCA) originates from the anterior/right coronary sinus above the level of the right cusp of the aortic valve and runs down in the right coronary sulcus or groove in the direction of

the crux of the heart. The three aortic sinuses are the dilatations of wall of ascending aorta immediately above the cusps of the aortic valve. The RCA supplies mainly the right atrium & the right ventricle and partly the left atrium & the left ventricle and the interventricular septum.

An abnormal origin of the RCA either may be asymptomatic or may be symptomatic and lead to angina pectoris, myocardial infarction or sudden death, even in the nonexistence of atherosclerosis [2,3] however the pathophysiologic foundation for this association is indistinct. The abnormal derivation of the right coronary artery is an uncommon presentation at birth and this anomaly was 1st expressed by White and Edwards in 1948 [1]. The abnormal RCA originates either from left coronary sinus or from the aortic wall above the level of the coronary sinus [4]. The prevalence of abnormal RCA has been reported in literature as < 1% [5]. Most of these anomalies are clinically benevolent; on the other hand others are linked with severe morbidity [3]. The occurrence of this anomaly in the white population, in the autopsy studies has been mentioned as 0.026% [6] but in other populations however, the prevalence is shown significantly elevated. In Japan, Kaku and colleagues [7] had examined 17,731 patients with coronary angiography in Japanese people from year 1968 and 1994 and found prevalence of abnormal RCA as 0.25% [3]. Topaz and co-workers [8] reported about an analogous numbers in their study and recorded that abnormal RCA was the most common coronary anomaly in people of Hispanic derivation. The screening CT coronary angiography had exposed origin of right coronary artery from the ascending aorta, about 1 cm above the left coronary sinus. The artery was traversing in between pulmonary trunk and ascending aorta before its subsequent next normal course. No any significant atherosclerotic plaque was found [9].

Despite the consequences of the grounds of the adverse associations, there is a necessity to study of those patients prospectively lying at the highest risk. Taylor and co-authors in 1992, [2] in their study of 52 patients having anomalous origin of the RCA recorded that 25% had died suddenly and in most cases they were asymptomatic. It has been mentioned that the anomalous RCA as second to the abnormal LCA, as the cardiac anomaly mostly associated with unexpected sudden cardiac death. Taylor and associates later in 1997 [10] did a blinded pathologic breakdown of 21 cases of anomalous origin of the RCA towards an effort to stratify such cases by risk. Despite review of

different anatomic variables including ostial size, length of intramural course, angle of take-off and the presence of symptoms, they could find only that an age of 30 years or older are associated with a lower occurrence of sudden cardiac death.

In anomalous RCA, the method of myocardial ischemia/angina pectoris is mainly dynamic and it is not due to atherosclerotic plaques. The potential causes of obstacle in blood flow are the ostial obstruction by nick like coronary orifice, compression of RCA and stretching of the RCA with aortic/pulmonary artery expansion [11]. Autopsy studies demonstrated diffuse irregular necrosis and fibrosis of myocardium suggestive of frequent episodes of miniature infarction. The probable cause of sudden unexpected death could be the sustained ventricular tachyarrhythmia due to an unstable myocardial substrate [4].

The selection of treatment for right coronary anomaly is divisive with some advocating revascularization in each and every one case. Projected options comprise translocation of the RCA to the aorta [12], ostioplasty (excision of the common wall between the RCA and the aorta) [13], and bypass grafting of the RCA (with optional ligation of the local artery proximal to the graft anastomosis to avoid competitive flow) [14]. However, the long-standing profits of such therapies have not yet been confirmed. The treatment for this condition is extra traditional in Japan. Kaku and associates [7] had studied 56 patients with an abnormal origin of the coronary arteries and treated them medically with drug β -blockers. More or less 9% of such patients experienced occurrence of hypotension and arrhythmias during exertion and no any death was detected to be directly correlated to the congenital abnormalities during 5 years of their follow-up.

The development of coronary arteries is a delicate, complex and delicately tuned progression which includes numerous interactions between several pathways, particularly in the pericardium and the embryonic myocardium. There still exists some disagreement on the precise origin of definite cellular constituents however an understanding of this exceedingly important developmental process is paramount to recognize some of the reasons of abnormal development of coronary arteries [15]. Abnormal starting point of coronary arteries can be basically categorized according to the ectopically originated coronary arteries. The method of coronary angiography is the advanced and modern investigating procedure for the diagnosis of coronary abnormalities with recognition of stenosis, ostial barrier, compression or stretching

of coronary arteries during ascending aorta and or pulmonary trunk distension.

Conclusion

Although an abnormal origin of RCA may be asymptomatic mostly but it's leading to angina pectoris due to insufficient coronary blood circulation, myocardial infarction by complete blockage of blood flow to an area and sudden unexpected death cannot be denied, even during the absence of atherosclerotic plaques. So, bringing this anomalous condition into the group of clinically insignificant lot is not justifiable, as some of them may lead to grave morbidity and may endanger the life. Conceptual and therapeutic debates remain because the diagnosis and the management of such patterns continue to be challenging. A good knowledge of the normal coronary artery development and its deviation can potentially help us explore new boulevard towards the management of ischemic heart disease caused by the abnormal coronary arteries.

Conflict of interest: None

References

1. White NK, Edwards JE. Anomalies of the coronary arteries. Report of four cases. Arch Pathol. 1948;45:766-71. [PubMed]
2. Taylor AJ, Rogan KM, Virmani R. Sudden cardiac death associated with isolated congenital coronary artery anomalies. J Am Coll Cardiol. 1992;20:640-7. [PubMed]
3. John S. Ho, Neil E. Strickman. Anomalous origin of the right coronary artery from the left coronary sinus. Case report and literature review. Tex Heart Inst J. 2002;29(1):37-9. [PMC free article] [PubMed]
4. Man-Hong J, Chung-Wah Siu, Hee-Hwa H, Ramond M, Stephen Wai-Luen L. Anomalous origin of the right coronary artery from the left coronary sinuses associated with early development of coronary artery disease. J Invasive Cardiol. 2004;16:466-8. [PubMed]
5. Luis RL, Vladimir MR, Eddy WO, Lorenzo DL. Aberrant origin of right coronary artery from left coronary sinus and course between the great arteries diagnosed by 64-slice computed tomography. The Internet J Cardiol. 2009;7(1):15-22.
6. Alexander RW, Griffiths GC. Anomalies of the coronary arteries and their clinical significance. Circulation. 1956;14:800-5. [PubMed]
7. Kaku B, Shimizu M, Yoshio H, Ino H, Mizuno S, Kanaya H, et al. Clinical features of prognosis

- of Japanese patients with anomalous origin of the coronary artery. *Jpn Circ J.* 1996;60:731-41. [PubMed]
8. Topaz O, DeMarchena EJ, Perin E, Sommer LS, Mallon SM, Chahine RA. Anomalous coronary arteries: angiographic findings in 80 patients. *Int J Cardiol.* 1992;34:129-38. [PubMed]
 9. Divya Mahajan, Gaurav Agnihotri and Rahat Brar. Anomalous Origin of Right Coronary Artery: An Anatomico-Clinical Perspective of 2 Cases. *Acta Inform Med.* 2012 Mar;20(1):56-57.
 10. Taylor AJ, Byers JP, Cheitlin MD, Virmani R. Anomalous right or left coronary artery from the contralateral coronary sinus: "high-risk" abnormalities in the initial coronary artery course and heterogeneous clinical outcomes. *Am Heart J.* 1997;133:428-35. [PubMed]
 11. Houman TM, Sean PB, Philip CC, Robert WS, Charles RM, William CD. Repair of anomalous origin of right coronary artery from the left sinus of valsalva. *Ann Thorac Surg.* 2008;85:2135-6. [PubMed]
 12. Di Lello F, Mnuik JF, Flemma RJ, Mullen DC. Successful coronary reimplantation for anomalous origin of the right coronary artery from the left sinus of Valsalva. *J Thorac Cardiovasc Surg.* 1991;102:455-6. [PubMed]
 13. Rinaldi RG, Carballido J, Giles R, Del Toro E, Porro R. Right coronary artery with anomalous origin and slit ostium. *Ann Thorac Surg.* 1994;58:829-32. [PubMed]
 14. Shah AS, Milano CA, Lucke JP. Anomalous origin of the right coronary artery from the left coronary sinus: case report and review of surgical treatments. *Cardiovasc Surg.* 2000;8:284-6. [PubMed]
 15. Gentian L, Jamil A. Coronary Arterial Development: A Review of Normal and Congenitally Anomalous Patterns. *Clin Cardiol.* 2014;37(2):126-30.
-

REDKART.NET

(A product of RF Library Services (P) Limited)
(Publications available for purchase: Journals, Books, Articles and Single issues)
(Date range: 1967 to till date)

The Red Kart is an e-commerce and is a product of RF Library Services (P) Ltd. It covers a broad range of journals, Books, Articles, Single issues (print & Online-PDF) in English and Hindi languages. All these publications are in stock for immediate shipping and online access in case of online.

Benefits of shopping online are better than conventional way of buying.

1. Convenience.
2. Better prices.
3. More variety.
4. Fewer expenses.
5. No crowds.
6. Less compulsive shopping.
7. Buying old or unused items at lower prices.
8. Discreet purchases are easier.

URL: www.redkart.net

Guidelines for Authors

Manuscripts must be prepared in accordance with "Uniform requirements for Manuscripts submitted to Biomedical Journal" developed by international committee of medical Journal Editors

Types of Manuscripts and Limits

Original articles: Up to 3000 words excluding references and abstract and up to 10 references.

Review articles: Up to 2500 words excluding references and abstract and up to 10 references.

Case reports: Up to 1000 words excluding references and abstract and up to 10 references.

Online Submission of the Manuscripts

Articles can also be submitted online from http://rfppl.co.in/customer_index.php.

1) First Page File: Prepare the title page, covering letter, acknowledgement, etc. using a word processor program. All information which can reveal your identity should be here. use text/rtf/doc/PDF files. Do not zip the files.

2) Article file: The main text of the article, beginning from Abstract till References (including tables) should be in this file. Do not include any information (such as acknowledgement, your name in page headers, etc.) in this file. Use text/rtf/doc/PDF files. Do not zip the files. Limit the file size to 400 Kb. Do not incorporate images in the file. If file size is large, graphs can be submitted as images separately without incorporating them in the article file to reduce the size of the file.

3) Images: Submit good quality color images. Each image should be less than 100 Kb in size. Size of the image can be reduced by decreasing the actual height and width of the images (keep up to 400 pixels or 3 inches). All image formats (jpeg, tiff, gif, bmp, png, eps etc.) are acceptable; jpeg is most suitable.

Legends: Legends for the figures/images should be included at the end of the article file.

If the manuscript is submitted online, the contributors' form and copyright transfer form has to be submitted in original with the signatures of all the contributors within two weeks from submission. Hard copies of the images (3 sets), for articles submitted online, should be sent to the journal office at the time of submission of a revised manuscript. Editorial office: Red Flower Publication Pvt. Ltd., 48/41-42, DSIDC, Pocket-II, Mayur Vihar Phase-I, Delhi - 110 091, India, Phone: 91-11-22754205, 45796900, 22756995. E-mail: author@rfppl.co.in. Submission page: http://rfppl.co.in/article_submission_system.php?mid=5.

Preparation of the Manuscript

The text of observational and experimental articles should be divided into sections with the headings: Introduction, Methods, Results, Discussion, References, Tables, Figures, Figure legends, and Acknowledgment. Do not make subheadings in these sections.

Title Page

The title page should carry

- 1) Type of manuscript (e.g. Original article, Review article, Case Report)
- 2) The title of the article, should be concise and informative;
- 3) Running title or short title not more than 50 characters;
- 4) The name by which each contributor is known (Last name, First name and initials of middle name), with his or her highest academic degree(s) and institutional affiliation;
- 5) The name of the department(s) and institution(s) to which the work should be attributed;
- 6) The name, address, phone numbers, facsimile numbers and e-mail address of the contributor responsible for correspondence about the manuscript; should be mentioned.
- 7) The total number of pages, total number of photographs and word counts separately for abstract and for the text (excluding the references and abstract);
- 8) Source(s) of support in the form of grants, equipment, drugs, or all of these;
- 9) Acknowledgement, if any; and
- 10) If the manuscript was presented as part at a meeting, the organization, place, and exact date on which it was read.

Abstract Page

The second page should carry the full title of the manuscript and an abstract (of no more than 150 words for case reports, brief reports and 250 words for original articles). The abstract should be structured and state the Context (Background), Aims, Settings and Design, Methods and Materials, Statistical analysis used, Results and Conclusions. Below the abstract should provide 3 to 10 keywords.

Introduction

State the background of the study and purpose of the study and summarize the rationale for the study or observation.

Methods

The methods section should include only information that was available at the time the plan or protocol for the study was written such as study approach, design, type of sample, sample size, sampling technique, setting of the study, description of data collection tools and methods; all information obtained during the conduct of the study belongs in the Results section.

Reports of randomized clinical trials should be based on the CONSORT Statement (<http://www.consort-statement.org>). When reporting experiments on human subjects, indicate whether the procedures followed were in accordance with the ethical standards of the responsible committee on human experimentation (institutional or regional) and with the Helsinki Declaration of 1975, as revised in 2000 (available at http://www.wma.net/e/policy/17-c_e.html).

Results

Present your results in logical sequence in the text, tables, and illustrations, giving the main or most important findings first. Do not repeat in the text all the data in the tables or illustrations; emphasize or summarize only important observations. Extra or supplementary materials and technical details can be placed in an appendix where it will be accessible but will not interrupt the flow of the text; alternatively, it can be published only in the electronic version of the journal.

Discussion

Include summary of key findings (primary outcome measures, secondary outcome measures, results as they relate to a prior hypothesis); Strengths and limitations of the study (study question, study design, data collection, analysis and interpretation); Interpretation and implications in the context of the totality of evidence (is there a systematic review to refer to, if not, could one be reasonably done here and now?, What this study adds to the available evidence, effects on patient care and health policy, possible mechanisms)? Controversies raised by this study; and Future research directions (for this particular research collaboration, underlying mechanisms, clinical

research). Do not repeat in detail data or other material given in the Introduction or the Results section.

References

List references in alphabetical order. Each listed reference should be cited in text (not in alphabetic order), and each text citation should be listed in the References section. Identify references in text, tables, and legends by Arabic numerals in square bracket (e.g. [10]). Please refer to ICMJE Guidelines (http://www.nlm.nih.gov/bsd/uniform_requirements.html) for more examples.

Standard journal article

[1] Flink H, Tegelberg Å, Thörn M, Lagerlöf F. Effect of oral iron supplementation on unstimulated salivary flow rate: A randomized, double-blind, placebo-controlled trial. *J Oral Pathol Med* 2006; 35: 540-7.

[2] Twetman S, Axelsson S, Dahlgren H, Holm AK, Källestål C, Lagerlöf F, et al. Caries-preventive effect of fluoride toothpaste: A systematic review. *Acta Odontol Scand* 2003; 61: 347-55.

Article in supplement or special issue

[3] Fleischer W, Reimer K. Povidone iodine antiseptics. State of the art. *Dermatology* 1997; 195 Suppl 2: 3-9.

Corporate (collective) author

[4] American Academy of Periodontology. Sonic and ultrasonic scalers in periodontics. *J Periodontol* 2000; 71: 1792-801.

Unpublished article

[5] Garoushi S, Lassila LV, Tezvergil A, Vallittu PK. Static and fatigue compression test for particulate filler composite resin with fiber-reinforced composite substructure. *Dent Mater* 2006.

Personal author(s)

[6] Hosmer D, Lemeshow S. Applied logistic regression, 2nd edn. New York: Wiley-Interscience; 2000.

Chapter in book

[7] Nauntofte B, Tenovou J, Lagerlöf F. Secretion and composition of saliva. In: Fejerskov O,

Kidd EAM, editors. Dental caries: The disease and its clinical management. Oxford: Blackwell Munksgaard; 2003. p. 7-27.

No author given

[8] World Health Organization. Oral health surveys - basic methods, 4th edn. Geneva: World Health Organization; 1997.

Reference from electronic media

[9] National Statistics Online – Trends in suicide by method in England and Wales, 1979-2001. www.statistics.gov.uk/downloads/theme_health/HSQ20.pdf (accessed Jan 24, 2005): 7-18. Only verified references against the original documents should be cited. Authors are responsible for the accuracy and completeness of their references and for correct text citation. The number of reference should be kept limited to 20 in case of major communications and 10 for short communications.

More information about other reference types is available at www.nlm.nih.gov/bsd/uniform_requirements.html, but observes some minor deviations (no full stop after journal title, no issue or date after volume, etc).

Tables

Tables should be self-explanatory and should not duplicate textual material.

Tables with more than 10 columns and 25 rows are not acceptable.

Table numbers should be in Arabic numerals, consecutively in the order of their first citation in the text and supply a brief title for each.

Explain in footnotes all non-standard abbreviations that are used in each table.

For footnotes use the following symbols, in this sequence: *, †, ‡, §.

Illustrations (Figures)

Graphics files are welcome if supplied as Tiff, EPS, or PowerPoint files of minimum 1200x1600 pixel size. The minimum line weight for line art is 0.5 point for optimal printing.

When possible, please place symbol legends below the figure instead of to the side.

Original color figures can be printed in color at the editor's and publisher's discretion provided the author agrees to pay.

Type or print out legends (maximum 40 words, excluding the credit line) for illustrations using double spacing, with Arabic numerals corresponding to the illustrations.

Sending a revised manuscript

While submitting a revised manuscript, contributors are requested to include, along with single copy of the final revised manuscript, a photocopy of the revised manuscript with the changes underlined in red and copy of the comments with the point to point clarification to each comment. The manuscript number should be written on each of these documents. If the manuscript is submitted online, the contributors' form and copyright transfer form has to be submitted in original with the signatures of all the contributors within two weeks of submission. Hard copies of images should be sent to the office of the journal. There is no need to send printed manuscript for articles submitted online.

Reprints

Journal provides no free printed reprints, however a author copy is sent to the main author and additional copies are available on payment (ask to the journal office).

Copyrights

The whole of the literary matter in the journal is copyright and cannot be reproduced without the written permission.

Declaration

A declaration should be submitted stating that the manuscript represents valid work and that neither this manuscript nor one with substantially similar content under the present authorship has been published or is being considered for publication elsewhere and the authorship of this article will not be contested by any one whose name (s) is/are not listed here, and that the order of authorship as placed in the manuscript is final and accepted by the co-authors. Declarations should be signed by all the authors in the order in which they are mentioned in the original manuscript. Matters appearing in the Journal are covered by copyright but no objection will be made to their reproduction provided permission is obtained from the Editor prior to publication and due acknowledgment of the source is made.

Approval of Ethics Committee

We need the Ethics committee approval letter from an Institutional ethical committee (IEC) or an institutional review board (IRB) to publish your Research article or author should submit a statement that the study does not require ethics approval along with evidence. The evidence could either be consent from patients is available and there are no ethics issues in the paper or a letter from an IRB stating that the study in question does not require ethics approval.

Abbreviations

Standard abbreviations should be used and be spelt out when first used in the text. Abbreviations should not be used in the title or abstract.

Checklist

- Manuscript Title
- Covering letter: Signed by all contributors
- Previous publication/ presentations mentioned, Source of funding mentioned
- Conflicts of interest disclosed

Authors

- Middle name initials provided.
- Author for correspondence, with e-mail address provided.
- Number of contributors restricted as per the instructions.
- Identity not revealed in paper except title page (e.g.name of the institute in Methods, citing previous study as 'our study')

Presentation and Format

- Double spacing
- Margins 2.5 cm from all four sides
- Title page contains all the desired information. Running title provided (not more than 50 characters)
- Abstract page contains the full title of the manuscript
- Abstract provided: Structured abstract provided for an original article.
- Key words provided (three or more)
- Introduction of 75-100 words

- Headings in title case (not ALL CAPITALS). References cited in square brackets
- References according to the journal's instructions

Language and grammar

- Uniformly American English
- Abbreviations spelt out in full for the first time. Numerals from 1 to 10 spelt out
- Numerals at the beginning of the sentence spelt out

Tables and figures

- No repetition of data in tables and graphs and in text.
- Actual numbers from which graphs drawn, provided.
- Figures necessary and of good quality (color)
- Table and figure numbers in Arabic letters (not Roman).
- Labels pasted on back of the photographs (no names written)
- Figure legends provided (not more than 40 words)
- Patients' privacy maintained, (if not permission taken)
- Credit note for borrowed figures/tables provided
- Manuscript provided on a CDROM (with double spacing)

Submitting the Manuscript

- Is the journal editor's contact information current?
- Is the cover letter included with the manuscript? Does the letter:
 1. Include the author's postal address, e-mail address, telephone number, and fax number for future correspondence?
 2. State that the manuscript is original, not previously published, and not under concurrent consideration elsewhere?
 3. Inform the journal editor of the existence of any similar published manuscripts written by the author?
 4. Mention any supplemental material you are submitting for the online version of your article. Contributors' Form (to be modified as applicable and one signed copy attached with the manuscript)

Red Flower Publication (P) Ltd.

Presents its Book Publications for sale

- | | |
|--|----------------------|
| 1. Biostatistics Methods for Medical Research (2019)
<i>by Sanjeev Sarmukaddam</i> | INR549/USD44 |
| 2. MCQs in Medical Physiology (2019) <i>by Bharati Mehta & Bharti Bhandari Rathore</i> | INR300/USD29 |
| 3. Synopsis of Anesthesia (2019) <i>by Lalit Gupta MBBS & Bhavna Gupta MBBS</i> | INR1195/USD95 |
| 4. Shipping Economics (2018) <i>by D. Amutha, Ph.D.</i> | INR345/USD27 |
| 5. Breast Cancer: Biology, Prevention and Treatment (2015)
<i>by Rana P. Singh, Ph.D. & A. Ramesh Rao, Ph.D. (JNU)</i> | INR395/USD100 |
| 6. Child Intelligence (2005) <i>by Rajesh Shukla, MD.</i> | INR150/USD50 |
| 7. Pediatric Companion (2001) <i>by Rajesh Shukla, MD.</i> | INR250/USD50 |

Order from

Red Flower Publication Pvt. Ltd.

48/41-42, DSIDC, Pocket-II

Mayur Vihar Phase-I

Delhi - 110 091(India)

Mobile: 8130750089, Phone: 91-11-45796900, 22754205, 22756995

E-mail: sales@rfppl.co.in

Special Note!

Please note that our all Customers, Advertisers, Authors, Editorial Board Members and Editor-in-chief are advised to pay any type of charges against Article Processing, Editorial Board Membership Fees, Postage & Handling Charges of author copy, Purchase of Subscription, Single issue Purchase and Advertisement in any Journal directly to Red Flower Publication Pvt. Ltd.

Nobody is authorized to collect the payment on behalf of Red Flower Publication Pvt. Ltd. and company is not responsible of respective services ordered for.